

# Clinical Outcomes After Implantation of 320°-Arc Length Intrastromal Corneal Ring Segments in Keratoconus

Leonardo Torquetti, MD, PhD,\* Priscila Cunha, MD,† Allan Luz, MD, PhD,‡ Sérgio Kwitko, MD,§ Márcio Carrion, MD,¶ Guilherme Rocha, MD,|| Armando Signorelli, MD,\*\* Sandro Coscarelli, MD,†† Guilherme Ferrara, MD,‡‡ Frederico Bicalho, MD,† Renato Neves, MD,§§ and Paulo Ferrara, MD, PHD‡‡

**Purpose:** To evaluate the clinical outcomes after implantation of a new 320°-arc length Ferrara intrastromal corneal ring segment (320-ICRS) in eyes of patients with keratoconus.

**Methods:** A multicentric nonrandomized study was conducted in which a new 320-ICRS was placed in 138 eyes of 130 patients with keratoconus. Uncorrected distance visual acuity (UDVA), corrected distance visual acuity (CDVA), keratometry, corneal volume, asphericity, lines of vision gain/loss, and vectorial analysis were assessed preoperatively and at the final follow-up visit after the procedure.

**Results:** The mean follow-up time was  $6.2 \pm 3.3$  (SD) months (range 3–12 months). Mean UDVA improved from 20/250 to 20/60. Mean CDVA improved from 20/100 to 20/40. Mean Q improved from  $-1.12 \pm 0.49$  preoperatively to  $-0.28 \pm 0.51$  postoperatively ( $P < 0.001$ ). Mean corneal volume increased from  $56.2 \pm 4.28$  mm<sup>3</sup> preoperatively to  $57.6 \pm 4.74$  postoperatively ( $P < 0.001$ ). Mean Km reduced from  $53.3 \pm 5.5$  D preoperatively to  $47.8 \pm 4.6$  D postoperatively ( $P < 0.001$ ). The change in UDVA, CDVA, and topographic astigmatism was statistically significant ( $P < 0.0001$ ).

**Conclusions:** The 320-ICRS can efficiently and safely improve visual acuity in keratoconus, modifying the corneal shape to a more physiologic, aspheric shape.

**Key Words:** Ferrara ring, keratoconus, intrastromal ring segments, 320-ICRS

(*Cornea* 2018;00:1–7)

Received for publication January 28, 2018; revision received May 31, 2018; accepted June 2, 2018.

From the \*Center for Excellence in Ophthalmology, Pará de Minas, Brazil; †Hospital São Geraldo, HC-UFMG, Belo Horizonte, Brazil; ‡Hospital de Olhos de Sergipe, Aracaju, Brazil; §Oftalmocentro, Porto Alegre, Brazil; ¶Carrion Eye Clinic, Santo Ângelo, Brazil; ||Hospital de Olhos de Brasília, Brasília, Brazil; \*\*Centro Campineiro de Microcirurgia Ocular, Campinas, Brazil; ††Ennio Coscarelli Eye Clinic, Belo Horizonte, Brazil; ‡‡Paulo Ferrara Eye Clinic, Belo Horizonte, Brazil; and §§EyeCare, São Paulo, Brazil. The authors have no funding to disclose.

The authors have no financial interest in Ferrara intrastromal corneal ring segments, except P. Ferrara and G. Ferrara, who are shareholders of Ferrara Ophthalmics. The other authors have no conflicts of interest to disclose.

Correspondence: Leonardo Torquetti, MD, PhD, Rua Capitão Teixeira, 415-B, Nossa Senhora das Graças-Pará de Minas, MG, Brazil 35660-051 (e-mail: leotorquetti@gmail.com).

Copyright © 2018 Wolters Kluwer Health, Inc. All rights reserved.

Keratoconus is progressive corneal thinning of unknown cause in which the cornea assumes a conical shape, with progressive irregular astigmatism and deterioration of visual acuity.<sup>1</sup> In the general population, the incidence of keratoconus is estimated to be between 50 and 230 per 100,000.<sup>2</sup>

Intrastromal corneal ring segments (ICRS) represent substantial evolution in management of keratoconus. Moreover, long-term data on ICRS procedures demonstrated promising results in topographic regularity, uncorrected distance visual acuity (UDVA) and corrected distance visual acuity (CDVA), indicating its effect in avoiding or at least postponing corneal transplantation in patients with keratoconus.<sup>3–8</sup> The main advantages of ICRS are safety,<sup>4</sup> reversibility,<sup>9</sup> stability,<sup>10</sup> and the fact that the surgical process does not affect the central corneal visual axis.

The 320-arc length Ferrara intrastromal corneal ring segment (AJL, Vitoria, Spain) (320-ICRS) is a new unique intracorneal ring design specially developed for more advanced types of keratoconus. It is available in a diameter of 5.7 mm and a thickness range of 150 to 300 μm. To our knowledge, there are no reports on the effect of insertion or implantation of a 320-ICRS on the postoperative outcome. This study aims at evaluating the clinical outcomes after implantation of a 320-ICRS in eyes of patients with keratoconus.

## METHODS

In a multicentric study, we prospectively evaluated the clinical outcomes of implantation of a 320-ICRS in 138 eyes of 130 patients with keratoconus. The patients were recruited and operated in 10 different surgical centers in Brazil. All patients were informed about inclusion in the study and provided informed consent in accordance with the Declaration of Helsinki. In addition, the study was approved by the local ethics committee of each center.

Forty-five eyes had the procedure performed using the manual technique; the femtosecond laser was used for tunnel creation in 93 eyes. After complete ophthalmic examination and a thorough discussion of the risks and benefits of surgery, the patients provided written informed consent. The primary indication for Ferrara ring implantation was contact lens intolerance and progression of ectasia. The progress of the disease was defined by worsening of

UDVA and CDVA, increasing intolerance to contact lens wear, and progressive corneal steepening documented by topography.

## CLINICAL MEASUREMENTS

### Preoperative and Postoperative Evaluation

All patients had complete ophthalmologic examination preoperatively and postoperatively. The outcome analysis comprised UDVA, CDVA, spherical equivalent (SE), central pachymetry, corneal volume, refractive error, corneal topographic astigmatism, and minimum and maximum keratometry (K) values. All data were obtained before and at the final visit after ICRS implantation. CDVA, slit-lamp evaluation, refraction, corneal topography, funduscopy, and tonometry were performed at each control visit. Anterior segment parameters were obtained by a corneal tomographer (Oculus Pentacam, Wetzlar, Germany). All clinical examinations were performed in a standardized manner according to the guidelines of the multicentric study.

On the first postoperative day, slit-lamp biomicroscopic examination was performed. Healing of the wound and migration of the segments were evaluated. At final follow-up examination, manifest refraction, UDVA and CDVA, and slit-lamp and topographic examinations were performed.

### Surgical Technique

The 320-ICRS was implanted using the manual technique or femtosecond laser-assisted procedure.

### Manual Technique

Surgery was performed under topical anesthesia after miosis was achieved with 2% pilocarpine. An eyelid speculum was used to expose the eye, and 2.5% povidone-iodine eye drops were instilled onto the cornea and conjunctival cul-de-sac. The visual axis was marked by pressing the Sinskey hook on the central corneal epithelium while asking the patient to fixate on the corneal light reflex of the microscope light. Using a marker tinted with gentian-violet tinted, a 5.0-mm optical zone and incision site were aligned to the desired axis in which the incision would be made.

The depth of a 1.0-mm, square diamond blade was set at 80% of corneal thickness at the incision site, and this knife is used to make the incision. Using a “stromal spreader,” a pocket was formed on each side of the incision. Specific 380-degree circular dissecting spatulas were inserted through the incision and gently pushed with some quick, rotary “back and forth” tunneling movements. After channel creation, the 320-ICRS was inserted using a modified McPherson forceps. The ICRS was adequately positioned with the aid of a Sinskey hook.<sup>7</sup>

### Femtosecond Laser Technique

The surgical procedure was performed under sterile conditions and topical anesthesia. Purkinje reflex was chosen

as the central point and was marked. A 5-mm marker was used to locate the exact ring channel. The tunnel depth was set at 75% of the thinnest corneal thickness on the tunnel location in the femtosecond laser cases.<sup>11–16</sup>

A 60-kHz femtosecond laser (LDV; Ziemer, Switzerland) or the IntraLase was used to create the ring channel. Particular attention was given to centralizing the suction ring to mark the central point to minimize decentration. The channel's inner diameter was set to 4.4 mm, the outer diameter was 5.6 mm, the ring energy used for channel creation was 1.30 J, and the entry cut energy was 1.30 J. Channel creation timing with the femtosecond laser was 15 seconds. The 320-ICRS was implanted immediately after channel creation before the bubbles disappeared, which reveals the exact tunnel location. After channel creation, the 320-ICRS was inserted using a modified McPherson forceps. The 320-ICRS was properly positioned with the aid of a Sinskey hook.

The postoperative regimen consisted of moxifloxacin 0.5% (Vigamox; Alcon, Forth Worth, TX) and dexamethasone 0.1% (Maxidex; Alcon, Forth Worth, TX) eye drops 4 times daily for 2 weeks. The patients were instructed to avoid rubbing the eye and to use preservative-free artificial tears frequently—polyethylene glycol 400 0.4% (Systane; Alcon, Forth Worth, TX).

### Statistical Analysis

Statistical analysis was performed using Minitab software (2007, Minitab Inc.). The Student *t* test for paired data was used to compare preoperative and postoperative data.

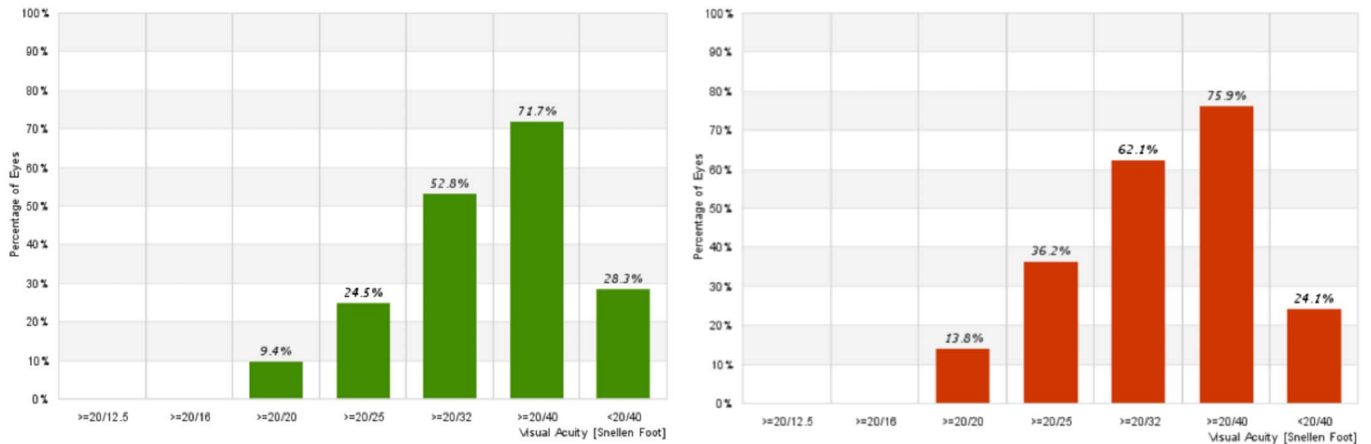
## RESULTS

There were 62 females and 68 males with a mean age of  $27 \pm 9.9$  years (range 10–63 years). The mean follow-up time was  $6.2 \pm 3.3$  (SD) months (range 3–12 months). Preoperative and postoperative UDVA, CDVA, SE, and pachymetry were obtained from all patients (Table 1). Median UDVA improved from 20/250 preoperatively to 20/60 postoperatively ( $P < 0.001$ ). Mean CDVA improved from 20/100

**TABLE 1.** Preoperative and Postoperative Evaluated Parameters

	Preoperative	Postoperative	<i>P</i>
UDVA*	20/250	20/60	<0.001
CDVA	20/100	20/40	<0.001
CDVA*	20/60	20/30	<0.001
SE	-7.02 ( $\pm 4.8$ )	-3.29 ( $\pm 3.8$ )	<0.001
Pachymetry	430 ( $\pm 47.8$ )	447 ( $\pm 53.8$ )	<0.001
Q	-1.25 ( $\pm 0.49$ )	-0.31 ( $\pm 0.51$ )	<0.001
Corneal volume	56.2 ( $\pm 4.28$ )	57.6 ( $\pm 4.74$ )	<0.001
Topographic astigmatism	4.62 ( $\pm 2.87$ )	2.74 ( $\pm 2.07$ )	<0.001
K1	50.5 ( $\pm 4.9$ )	46.0 ( $\pm 4.4$ )	<0.001
K2	55.2 ( $\pm 5.6$ )	49.0 ( $\pm 4.6$ )	<0.001
Km	53.3 ( $\pm 5.5$ )	47.8 ( $\pm 4.6$ )	<0.001

\*Median  $\Delta Q = 0.94$ .



**FIGURE 1.** CDVA after implantation of 320-ICRS (3 and 6 months of follow-up). Left = 3 months; right = 6 months.

preoperatively to 20/40 postoperatively ( $P < 0.001$ ). Median CDVA improved from 20/60 preoperatively to 20/30 postoperatively ( $P < 0.001$ ). Mean preoperative SE was  $-7.02 \pm 4.80$  D preoperatively and  $-3.29 \pm 3.8$  D postoperatively ( $P < 0.001$ ). Mean central pachymetry increased from  $430 \pm 47.8$  D preoperatively to  $447 \pm 53.8$  D postoperatively ( $P < 0.001$ ). Two or more lines of CDVA were gained in 87% of eyes. Four percent of eyes lost 1 line of vision. All these eyes had preoperative CDVA better than 20/40. There was progressive improvement in CDVA and lines of CDVA gained from 3 to 6 months of follow-up (Figs. 1, 2).

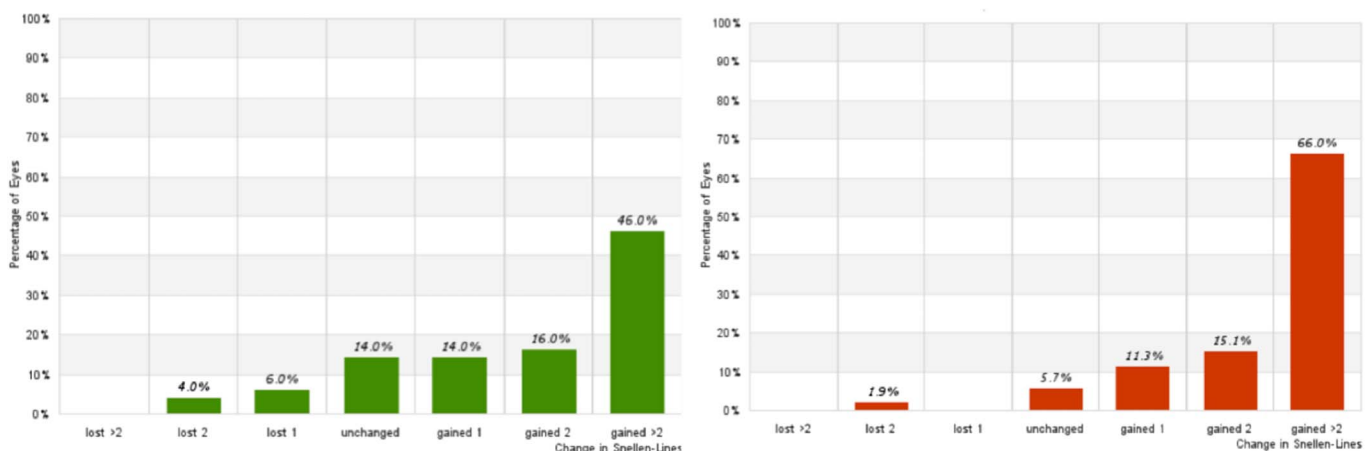
During the follow-up period after ICRS implantation, there were no cases of segment extrusion. There were 4 cases of migration, which were excluded from the statistical analysis. All these cases were performed with the manual technique (8.8% of manual cases). No intraoperative complications were observed with the femtosecond laser technique. There were 2 (4.4%) cases of intraoperative perforation with the manual method, which were excluded from the study.

Preoperative and postoperative anterior segment parameters are described in Table 1. Mean Q improved from  $-1.12$

$\pm 0.49$  preoperatively to  $-0.28 \pm 0.51$  postoperatively. Mean corneal volume increased from  $56.2 \pm 4.28$  preoperatively to  $57.6 \pm 4.74$  mm<sup>3</sup> postoperatively ( $P < 0.001$ ). Mean K1 reduced from  $50.5 \pm 4.9$  D preoperatively to  $46.0 \pm 4.4$  D postoperatively. Mean K2 decreased from  $55.2 \pm 5.6$  D preoperatively to  $49.0 \pm 4.6$  D postoperatively. Mean Km reduced from  $53.3 \pm 5.5$  D preoperatively to  $47.8 \pm 4.6$  D postoperatively (Fig. 3). The change in Q, corneal volume, topographic astigmatism, K1, K2, and Km was statistically significant ( $P < 0.0001$ ).

We evaluated the keratometry change after implantation of the 320-ICRS, compared to preoperative keratometry. Steep corneas had a more significant flattening effect compared with flat corneas (Table 2).

When considering the keratoconus type (oval, nipple, or astigmatic), we did not find significant differences among them, regarding the change in keratometry after 320-ICRS implantation (Table 3). The topographic astigmatism change was more significant in astigmatic types of keratoconus (Table 4). The vectorial analysis of refraction and keratometry showed poor predictability of results after implantation of the 320-ICRS (Fig. 4).



**FIGURE 2.** Lines of CDVA gain/lost after implantation of 320-ICRS (3 and 6 months of follow-up). Left = 3 months; right = 6 months.

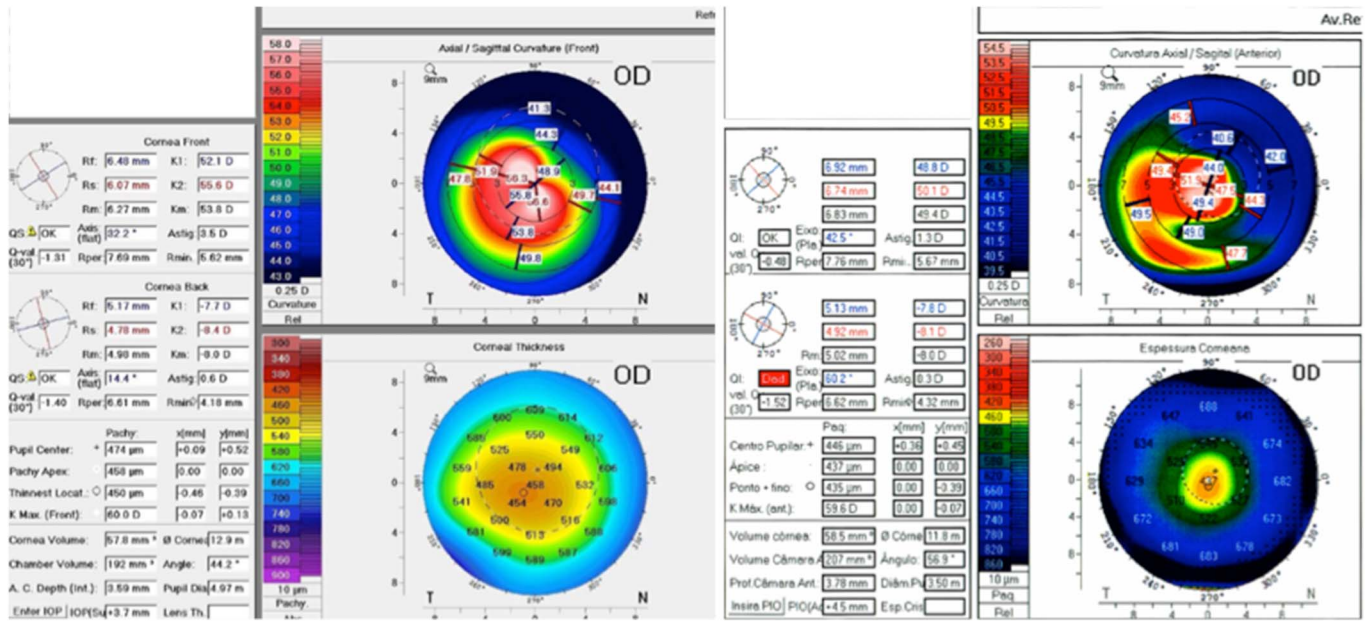


FIGURE 3. Preoperative (left) and postoperative (right) corneal tomography.

**DISCUSSION**

The 3 main advantages of the 320-ICRS over the standard 160-degree arc length ICRS are 1) significant asphericity change,<sup>17,18</sup> 2) significant corneal flattening,<sup>17,18</sup> and 3) implantation of a single segment.

ICRSs are available from 90-arc length to 210-arc length (90 degrees, 120 degrees, 140 degrees, 160 degrees, and 210 degrees) with different thicknesses ranging from 150 to 350 μm in 50-μm steps. Several studies have shown the role and behavior of each arc length and thickness on ICRS surgery.<sup>14,17,18</sup> It is accepted that the goals of ICRS implantation are 1) reduction of corneal irregularity and irregular astigmatism; 2) corneal flattening and myopia corneal prolatism reduction; and 3) better visual performance expressed through visual acuity lines gained. For achieving these goals, ICRSs in different arc lengths and thickness combinations lead to corneal changes and desired improvement.

Reintroduction of a long-arc ICRS has the primary objective of increasing corneal flattening and prolatism reduction, especially for the nipple type of keratoconus and advanced cases.<sup>19</sup> Few publications are available, and first results were recently published. Jadidi et al<sup>19,20</sup> published their results and complications using a 355-degree arc ICRS, and recently, Sadooghi et al<sup>21</sup> released their results using a 340-degree arc ICRS.

Kwitko and Severo<sup>22</sup> reported that keratoconus with central ectasia had significantly better results after sym-

metrical implantation. This is true, and probably, these cases may have done better if implanted with the 320-ICRS, which was not available when that study was published. Implantation of a single segment is advantageous because of less corneal trauma, less risk of infection and extrusion, besides less chance of haloes in the postoperative period.

A positive correlation was found between ring thickness and ΔQ; that is, the thicker the ring, the more reduction of the excess of prolatism effect on the cornea. A positive correlation was also found between ring thickness and ΔK; that is, the thicker the ring, the more flattening effect on the cornea.

We observed a progressive flattening effect of the 320-ICRS. This can be explained by its significant arc length, which produces a “new limbus” in the cornea, which changes progressively after implantation. This behavior is desirable in advanced keratoconus cases but not in mild ones, which are a relative contraindication for its use. The corneal changes after 320-ICRS occur in the whole area central to the ICRS; for this reason, we could consider this segment as a “new limbus.”

Colin et al,<sup>6</sup> in a 2-year follow-up study after implantation of Intacs, described a gain of 1 or more lines of CDVA in 61.0% eyes at 1 year and 68.3% eyes at 2 years. Fewer than 15% of eyes experienced a CDVA loss of 1 or more lines

**TABLE 2.** Evaluation of Variation of Mean Postoperative Keratometry According to Preoperative Keratometry

	Preoperative	Postoperative	P	ΔKm
<50.00 D	47.77 (±1.67)	44.24 (±2.63)	<0.001	3.70
50.00–60.00 D	52.9 (±2.37)	47.7 (±3.07)	<0.001	5.19
>60.00 D	63.3 (±3.2)	55.3 (±4.7)	<0.001	8.23

**TABLE 3.** Evaluation of Variation of Mean Postoperative Keratometry According to Keratoconus Type

	Preoperative	Postoperative	P	ΔKm
Oval	50.8 (±4.83)	46.1 (±4.61)	<0.001	4.64
Nipple	51.7 (±2.45)	46.9 (±2.81)	<0.001	4.78
Astigmatic	55.1 (±4.98)	51.09 (±6.17)	<0.001	4.07

**TABLE 4.** Evaluation of Variation of Mean Postoperative Topographic Astigmatism According to Keratoconus Type

	Preoperative	Postoperative	P	Δ Topographic Astigmatism
Oval	4.8 (±2.12)	2.84 (±2.13)	<0.001	1.95
Nipple	2.03 (±1.09)	1.74 (±1.13)	0.284	0.29
Astigmatic	8.50 (±1.55)	5.01 (±2.50)	<0.001	3.43

during the 2 years after Intacs implantation. There was CDVA loss of 1 or more lines in 14.6% of eyes.

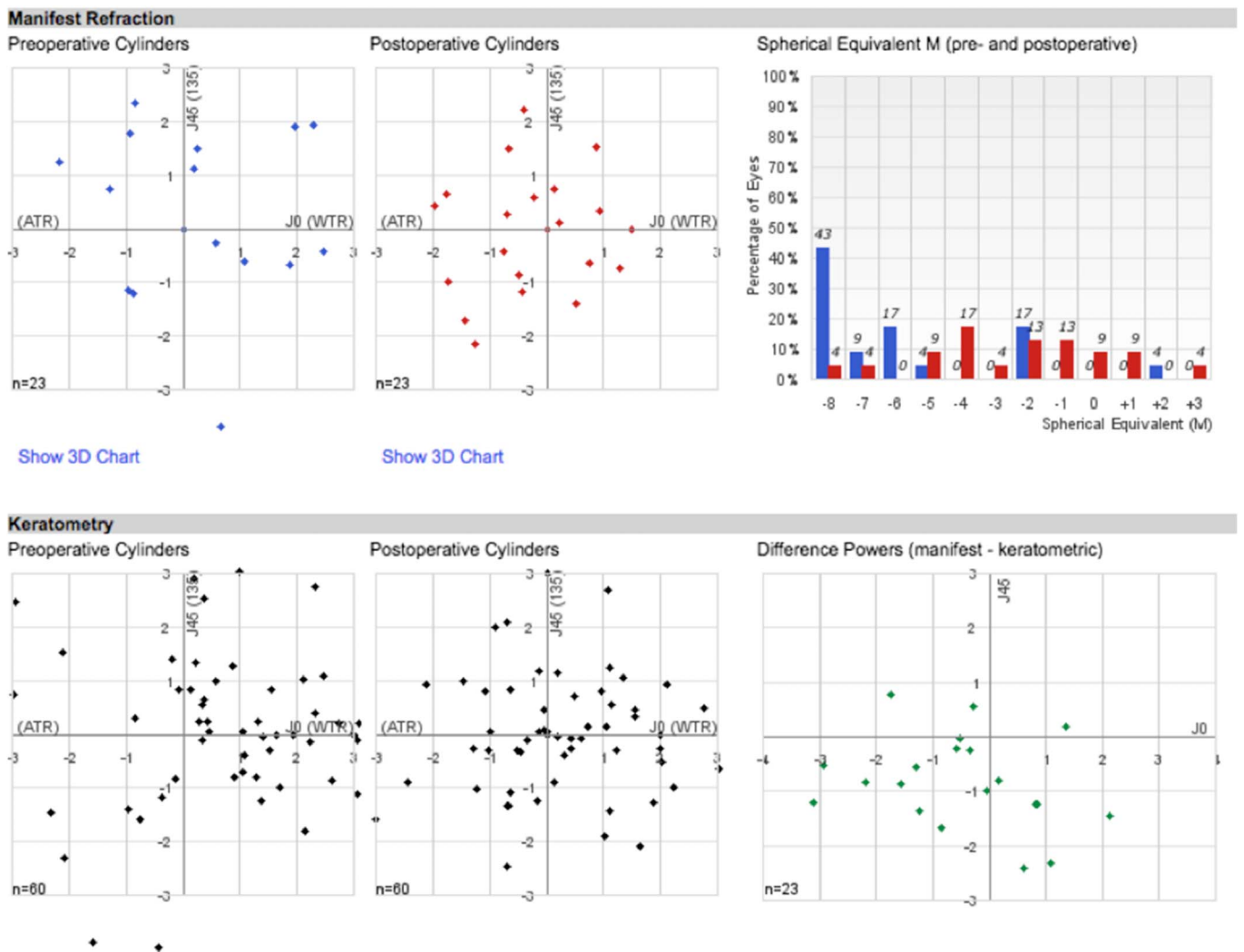
In the present study, we observed that 3 months after ICRS implantation, 76% of eyes gained 1 or more lines of CDVA. Six months after surgery, 92.4% of eyes gained 1 or more lines of CDVA (Fig. 2). These data reinforce the progressive effect of 320-ICRS along the time.

Our results are similar to the 355-degree arc report,<sup>19</sup> with significant improvement in UDVA, CDVA, and SE. On the other hand, the 340-degree arc report<sup>21</sup> showed different

results, with a lower percentage of patients gaining at least 2 lines of UDVA and no statistical significance in CDVA improvement ( $P = 0.09$ ), with only 50.0% of patients gaining at least 2 lines of CDVA. Sadoughi et al<sup>21</sup> related this poor result to the advanced stage of the disease (patients with  $Km > 55.0$  D and  $K2 > 57.0$  D).

In the current study, there were 4 cases of postoperative ICRS migration and 2 cases of intraoperative perforation. Jadidi et al<sup>19</sup> enrolled 5 patients in a study of the Keraring 355-degree arc ICRS using a femtosecond laser for tunnel creation. In all cases, postoperative complications happened, and the worst one was corneal melting, near the incision site. Proximity between the ICRS tip and the incision is the leading risk factor for extrusion, infection, and corneal melting. The 320-ICRS, in theory, can provide similar corneal changes (compared with the 355-ICRS); the main advantage of this ICRS is to be 20 degree gap on each side, far from the incision, what makes it safer to be used.

This study suggests that the ideal patients to be implanted with the 320-ICRS are those with central cones,



**FIGURE 4.** Vectorial analysis (vector analysis).

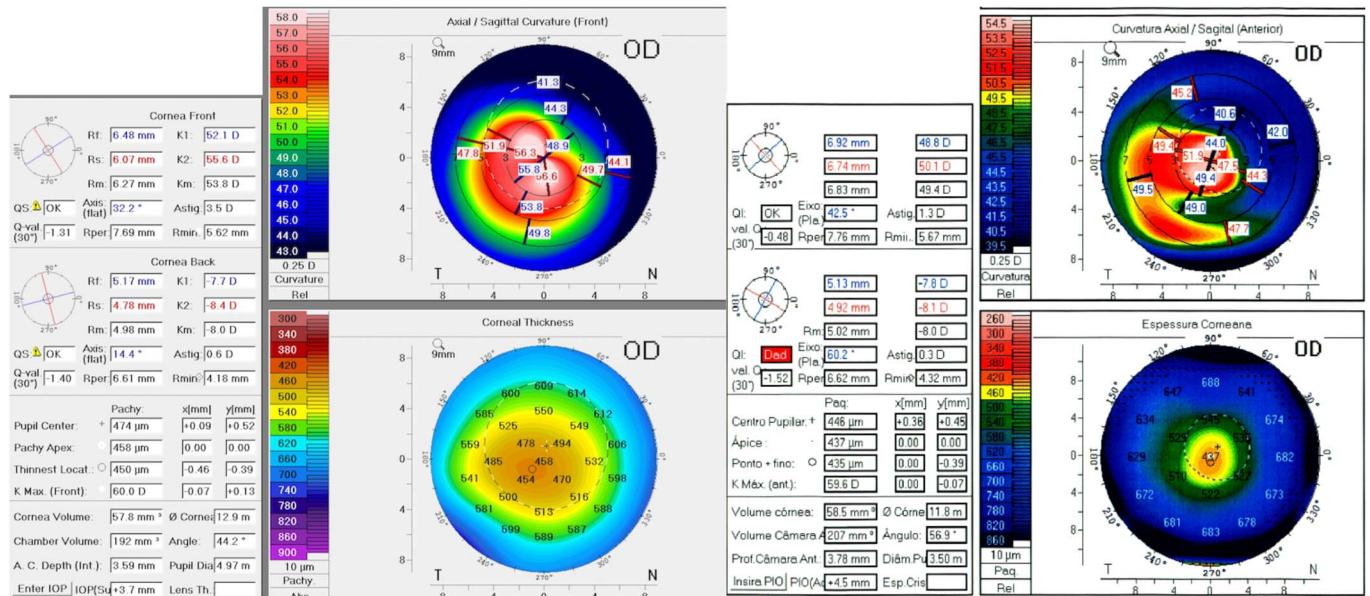


FIGURE 5. Preoperative (left) and postoperative (right) corneal tomography in asymmetrical keratoconus.

hyperprolate corneas, low-to-moderate astigmatism, and CDVA worse than 20/40. Because it causes significant changes in Q and Km, it should be reserved for moderate to advanced cases of keratoconus. The more advanced the case, the more significant the change after 320-ICRS implantation (Table 2). It should be avoided in asymmetric and mild<sup>23</sup> keratoconus because it can overcorrect and produce unpredictable/unreasonable results (Fig. 5) because of its uniform flattening effect and persistence of asymmetry after its implantation in asymmetric ectasias.

We found a significant increase in corneal thickness after ICRS implantation. This can be explained by theoretical corneal collagen remodeling induced by implantation of the ICRS. Acting as “spacers,” the ring segments could interfere in corneal collagen turnover, with consequent increase in central corneal pachymetry.<sup>24</sup>

One limitation of the study was the lack of a control group. However, several studies in the literature describe the results of other ICRS designs and arc length that could be compared with these first results of the 320-ICRS.

The 320-ICRS improved all parameters studied. Despite that, it does not provide a predictable refractive result, as demonstrated by the vectorial analysis (Fig. 4). Therefore, it should be used as a means to restore the cornea to a more physiologic shape, and a second refractive procedure (eg, phakic intraocular lens) may be required to achieve a better refractive outcome.<sup>25</sup>

In summary, our results suggest that the 320-ICRS might improve visual acuity in keratoconus, modifying the corneal shape to a more physiologic, aspheric shape. Further randomized controlled studies are needed to confirm our findings and also the safety of this new ring segment.

REFERENCES

1. Espandar L, Meyer J. Keratoconus: overview and update on treatment. *Middle East Afr J Ophthalmol.* 2010;17:15–20.

2. Gordon-Shaag A, Millodot M, Shneur E. The epidemiology and etiology of keratoconus. *Int J Keratoconus Ectatic Corneal Dis.* 2012;1:7–15.
3. Colin J, Velou S. Implantation of Intacs and a refractive intraocular lens to correct keratoconus. *J Cataract Refract Surg.* 2003;29:832–834.
4. Kymionis GD, Siganos CS, Tsiklis NS, et al. Long-term follow-up of Intacs in keratoconus. *Am J Ophthalmol.* 2007;143:236–244.
5. Colin J, Cochener B, Savary G, et al. Correcting keratoconus with intracorneal rings. *J Cataract Refract Surg.* 2000;26:1117–1122.
6. Colin J, Cochener B, Savary G, et al. INTACS inserts for treating keratoconus: one-year results. *Ophthalmology.* 2001;108:1409–1414.
7. Siganos CS, Kymionis GD, Kartakis N, et al. Management of keratoconus with Intacs. *Am J Ophthalmol.* 2003;135:64–70.
8. Siganos D, Ferrara P, Chatzinikolas K, et al. Ferrara intrastromal corneal rings for the correction of keratoconus. *J Cataract Refract Surg.* 2002;28:1947–1951.
9. Piñero DP, Alió JL, El Kady B, et al. Refractive and aberrometric outcomes of intracorneal ring segments for keratoconus: mechanical versus femtosecond-assisted procedures. *Ophthalmology.* 2009;116:1675–1687.
10. Torquetti L, Berbel RF, Ferrara P. Long-term follow-up of intrastromal corneal ring segments in keratoconus. *J Cataract Refract Surg.* 2009;35:1768–1773.
11. Kubaloglu A, Sari ES, Cinar Y, et al. Comparison of mechanical and femtosecond laser tunnel creation for intrastromal corneal ring segment implantation in keratoconus: prospective randomized clinical trial. *J Cataract Refract Surg.* 2010;36:1556–1561.
12. Lisa C, García-Fernandez M, Madrid-Costa D, et al. Femtosecond laser-assisted intrastromal corneal ring segment implantation for high astigmatism correction after penetrating keratoplasty. *J Cataract Refract Surg.* 2013;39:1660–1667.
13. Coimbra CC, Gomes MT, Campos M, et al. Femtosecond assisted intrastromal corneal ring (ICR) implantation for the treatment of corneal ectasia. *Arq Bras Oftalmol.* 2012;75:126–130.
14. Coskunseven E, Kymionis GD, Bouzoukis DI, et al. Single intrastromal corneal ring segment implantation using the femtosecond laser after radial keratotomy in a keratoconic patient. *J Cataract Refract Surg.* 2009;35:197–199.
15. Yeung SN, Ku JYF, Lichtinger A, et al. Efficacy of single or paired intrastromal corneal ring segment implantation combined with collagen crosslinking in keratoconus. *J Cataract Refract Surg.* 2013;39:1146–1151.
16. Pinero DP, Alió JL, El Kady B, et al. Corneal aberrometric and refractive performance of 2 intrastromal corneal ring segment models in early and moderate ectatic disease. *J Cataract Refract Surg.* 2010;36:102–109.

17. Ferrara P, Torquetti L. Clinical outcomes after implantation of a new intrastromal corneal ring with a 210-degree arc length. *J Cataract Refract Surg*. 2009;35:1604–1608.
18. Ferrara G, Torquetti L, Ferrara P, et al. Intrastromal corneal ring segments: visual outcomes from a large case series. *Clin Exp Ophthalmol*. 2012;40:433–439.
19. Jadidi K, Mosavi SA, Nejat F, et al. Intrastromal corneal ring segment implantation (keraring 355°) in patients with central keratoconus: 6-month follow-up. *J Ophthalmol*. 2015;2015:916385.
20. Jadidi K, Mosavi SA, Nejat F. Complications of intracorneal ring implantation (keraring 355°) using a femtosecond laser for channel creation. *Int J Kerat Ectatic Cor Dis*. 2014;3:53–56.
21. Sadoughi MM, Einollahi B, Veisi AR, et al. Femtosecond laser implantation of a 340-degree intrastromal corneal ring segment in keratoconus: short-term outcomes. *J Cataract Refract Surg*. 2017;43:1251–1256.
22. Kwitko S, Severo NS. Ferrara intracorneal ring segments for keratoconus. *J Cataract Refract Surg*. 2004;30:812–820.
23. Rodrigues P, Ferrara G, Ferrara P, et al. Intrastromal corneal ring segments implantation in patients with mild keratoconus. *Int J Kerat Ectatic Cor Dis*. 2014:122–126.
24. Flynn BP, Bhole AP, Saeidi N, et al. Mechanical strain stabilizes reconstituted collagen fibrils against enzymatic degradation by mammalian collagenase matrix metalloproteinase 8 (MMP-8). *PLoS One*. 2010;5:e12337.
25. Alfonso JF, Lisa C, Fernandez-Vega L, et al. Intrastromal corneal ring segments and posterior chamber phakic intraocular lens implantation for keratoconus correction. *J Cataract Refract Surg*. 2011;37:706–713.