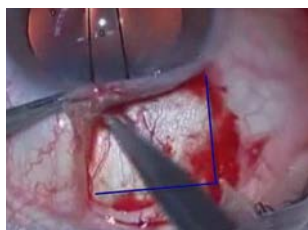


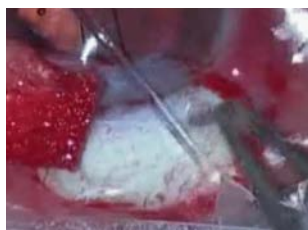# ESNOOPER CLIP

## General Surgical Procedure

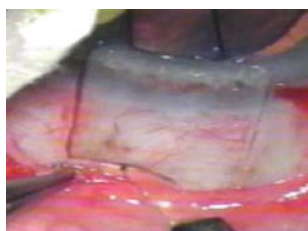
Implantation Protocol by Jordi Loscos Arenas MD, PhD (Barcelona)



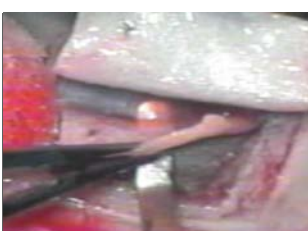PERITOMY



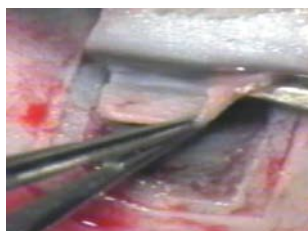
CAUTERIZATION



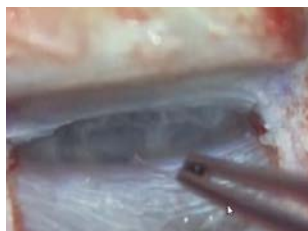SUPERFICIAL SCLERAL FLAP  
(2/3 THICKNESS)



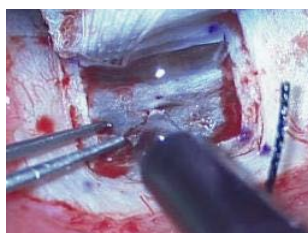
DEEP FLAP 4X4 MM



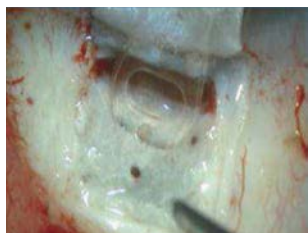RESECTION OF THE DEEP FLAP



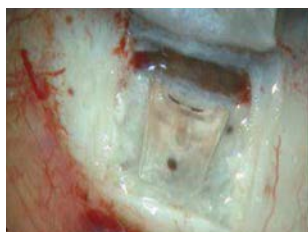PEELING AND POLISHING  
OF THE OUTER WALL



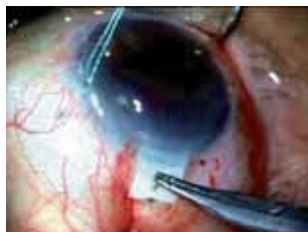SUPRACILIARY SPACE



NOTCHED PLATE INSERTION  
IN THE SUPRACILIARY SPACE



SECOND PLATE FOLDING ON  
THE INTRASCLERAL LAKE



SINGLE CENTRAL SCLERAL  
POINT AND CONJUNCTIVAL  
CLOSURE

Dissection of the superficial scleral flap measuring 5 x 5 mm, at a depth of 2/3 of the scleral thickness and that penetrates 1.5 to 2 mm into the clear cornea.

We mark a deep flap measuring 4 x 4 mm. We locate the correct dissection plane causing a small choroidal hernia in the vertex of the deep flap, serving as a reference.

Once we locate the correct dissection plane, we continue releasing the lateral pillars, pulling upwards and not forward of the scleral flap until the scleral spur is passed and the trabeculo-Descemet's membrane exposed, advancing a few millimeters on the Descemet membrane. We then resect the deep flap.

We locate the canal in front of the scleral spur and due to the presence of filiform blood on the sides of the pillars. We then peel the outer wall of the canal.

Using a scarifier we enter the supraciliary space and proceed to implant in it the supraciliary implant portion that is fixed in the supraciliary space by its lateral notches.

**Subsequently, the implant is bent, leaving one plate at supraciliary level and another in the intrascleral.**

We suture the scleral flap with a single central point and then the conjunctiva.