

# Refractive, Tomographic and Biomechanical Outcomes after Implantation of Ferrara ICRS in Keratoconus Patients

José M Salgado-Borges, Cláudia Costa-Ferreira, Manuel Monteiro, José Guilherme-Monteiro, Leonardo Torquetti Paulo Ferrara, Renato Ambrósio Jr

## ABSTRACT

**Background:** Nowadays, ICRS are a step in the treatment of keratoconus. The purpose of this study was to evaluate the refractive effect and the tomographic and biomechanical parameters in keratoconus patients implanted with Ferrara ICRS, and their stability after 18 months.

**Materials and methods:** Twenty eyes of 20 keratoconus patients implanted with ICRS were evaluated. The average follow-up was 18 months. UDVA, CDVA, biomicroscopy, tomography (Pentacam) and biomechanics (ORA) of the cornea were evaluated before and after surgery. For the comparison of groups, the Wilcoxon test was used.

**Results:** The mean UDVA improved from 1.00 to 0.30 and the mean CDVA improved from 0.51 to 0.12; both were statistically significant ( $p = 0.0001$ ). The average keratometry decreased from 50.7D to 47.5D ( $p = 0.0003$ ), and the average astigmatism decreased from 5.5D to 3.5D ( $p = 0.0058$ ). The mean CCT did not change significantly after surgery, but the mean TPP increased from 441.2 to 455.2  $\mu\text{m}$  ( $p = 0.004$ ). There was a significant reduction in the anterior cornea elevation, both the central (from 16.2-8.8;  $p = 0.0066$ ) and the minimum (from -43.2 to -57.1;  $p = 0.0228$ ). No significant change was found for posterior corneal elevation and for biomechanical parameters (hysteresis or CRF).

**Discussion:** There was a significant improvement of UDVA and CDVA after ICRS implantation, in keratoconic eyes. There was a significant and stable corneal flattening, and a decrease of the astigmatism. Corneal biomechanical parameters did not change.

**Keywords:** Biomechanics, Intracorneal ring segments, Ferrara rings, Keratoconus, Tomography.

**How to cite this article:** Salgado-Borges JM, Costa-Ferreira C, Monteiro M, Guilherme-Monteiro J, Torquetti L, Ferrara P, Ambrósio R Jr. Refractive, Tomographic and Biomechanical Outcomes after Implantation of Ferrara ICRS in Keratoconus Patients. *Int J Keratoco Ectatic Corneal Dis* 2012;1(1):16-21.

**Source of support:** Nil

**Conflict of interest:** Dr Ambrósio is Consultant of Oculus, Dr Ferrara has a financial interest in Ferrara intrastromal corneal ring.

## BACKGROUND

Keratoconus is a relatively common corneal disease, with a prevalence usually referred as 1:2000; the condition affects both sexes with roughly the same frequency.<sup>1</sup> The disease is characterized by a noninflammatory progressive thinning of unknown cause in which the cornea assumes a conical

shape. Usually both the eyes are affected, although often with a lag. This disease leads to irregular astigmatism and myopia and, in advanced stages, opacity of the apex of the cornea.

The treatment of choice varies according to the stage of the disease. In the early stages, eyeglasses and contact lenses are used for optical correction, without the need of any surgical procedure. Cross-linking has been used as an alternative in cases of progressive keratoconus.<sup>2-4</sup> Later, when an acceptable visual acuity can no longer be attained or when contact lenses are no longer tolerated, surgical treatment is necessary in order to stabilize and flatten the cornea. For a long-time, the only available option was the corneal transplantation, which continues to be the best option in cases of significant corneal scarring and in very steep corneas. More recently, intrastromal corneal ring segments (ICRS) emerged as a surgical alternative to at least delay, if not eliminate, the need for lamellar or penetrating keratoplasty. During the last 20 years, following the initial work of Nosé et al,<sup>5</sup> several models of ICRS were developed for the treatment of keratoconus and other corneal irregularities, such as ectasias after refractive surgery.<sup>6,7</sup> The two most commonly used models in clinical practice are the Intacs<sup>®</sup> and Ferrara rings<sup>®</sup>. These two options, consisting of segments of circle in PMMA, are relatively similar. The principal difference between them is their radius of curvature and consequently the proximity to the center of the cornea. Ferrara rings, because of their smaller radius of curvature (4.4 mm internal radius vs 6.77 mm) are closer to the center, thus presumably having a greater flattening effect.<sup>4</sup> Recently, a new model of Ferrara ICRS with 210° of arc was developed to improve visual acuity and reduce corneal steepening in selected patients.<sup>8</sup>

Since 2008, we have been studying the tomographic, biomechanical and refractive changes induced by the implantation of the Ferrara ICRS.<sup>6</sup> The aim of this study was: (1) To evaluate the correlation between the refractive effect and the tomographic data obtained with Pentacam (Oculus Optikgerate GmbH) in patients with keratoconus grades II and III, implanted with the Ferrara ICRS, (2) to describe the biomechanical profile of these patients with the Ocular Response Analyzer<sup>®</sup> (ORA) and, (3) to show the stability of the procedure at an average of 18 months after surgery.

## MATERIALS AND METHODS

In this study, we retrospectively reviewed the charts of 20 eyes of 20 patients with keratoconus grade II/III, according to the Amsler-Krumeich classification grading system, in which the Ferrara ICRS were implanted. Informed consent was obtained from all the participants and the study was reviewed by the local ethics committee.

The age of patients ranged from 24 to 46 years (31.9 ± 6.2). The minimal postoperative follow-up was one year; the average was 18.0 ± 4.0 months (range: 14-25 months).

To qualify for the study, the patients should be contact lens intolerant and/or have evidence of progression of the ectasia. The progression of the disease was defined by: Worsening of UDVA and CDVA, progressive intolerance to contact lens wear and progressive corneal steepening documented by the topography. Two or more lines of UDVA and/or CDVA worsening and at least 2D of increase in mean keratometry given by Pentacam were required to define progression of disease.

Preoperatively, all patients underwent a complete ophthalmic examination. The refraction was determined and the UDVA and CDVA were evaluated in the logMAR scale; the biomicroscopy, tomography and biomechanics of the cornea were also evaluated. For the tomographic study, we used the Pentacam (Oculus Optikgerate GmbH), determining the preoperative and postoperative keratometry, corneal astigmatism, CCT, TPP and the qualitative anterior and posterior elevation of the cornea. Biomechanical analysis was performed with the ORA (Ocular Response Analyzer, Reichert Inc, Buffalo, NY, USA), determining the preoperative and postoperative CH and CRF.

Patients were excluded if any of the following criteria applied after preoperative examination: Advanced keratoconus with curvatures over 62 diopters and significant apical opacity and scarring, hydrops, thin corneas with thickness below 300 micron in the ring track (evaluated by Pentacam pachymetric map) and intense atopia (these should be treated before the implant).

All surgeries were performed by the same surgeon (JSB) using the manual technique for the ICRS implantation, as previously described.<sup>10-13</sup> The rings were implanted according to the Ferrara Ring Nomogram.<sup>13</sup> A single segment was implanted in 11 eyes and a pair of segments was implanted in nine eyes.

After surgery ketorolac drops were used every 15 minutes for 3 hours, and a combination of 0.1% dexamethasone and 0.3% moxifloxacin or ciprofloxacin drops was used every 4 hours for 7 days as well as lubricant eye drops every 6 hours for 30 days.

The results are presented as mean ± standard deviation. For comparison of groups, the Wilcoxon test for nonparametric samples was used. Values of  $p < 0.05$  were considered statistically significant.

## RESULTS

The minimal postoperative follow-up was one year; the average was 18.0 ± 4.0 months (range: 14-25 months). In the preoperative study, all patients had UDVA of 1.00 logMAR. Postoperatively, at the last follow-up visit, the UDVA was 0.30 ± 0.258 (range: 0-1.00) ( $p = 0.0001$ ). The CDVA improved from 0.51 ± 0.299 (range: 0.18-1.00) to 0.12 ± 0.128 (range: 0-0.48) ( $p = 0.0001$ ). The CDVA improved in all patients but one, which remained stable, with no change in CDVA. However, this patient had an improvement of the UDVA (1.00-0.60) (Table 1).

The average keratometry decreased from 50.7 ± 4.2D (range: 44.5-58.4) preoperatively to 47.5 ± 3.7D (range: 42.7-54.8) after surgery ( $p = 0.0003$ ), which corresponded to an average reduction of the astigmatism of 5.5 ± 3.0D (range: 0.6-11.4) to 3.5 ± 2.5D (range: 0.9-11.4) ( $p = 0.0058$ ) (Table 1). The mean CCT did not change significantly after surgery (473.2 ± 43.6 μm vs 477.7 ± 46.4 μm). The mean TPP, however, increased significantly from 441.2 ± 48.8 to 455.2 ± 53.4 μm ( $p = 0.0040$ ) (Table 2). There was a statistically significant reduction of the anterior cornea elevation, both the central (from 16.2 ± 23.8-8.8±19.7;  $p = 0.0066$ ) and the minimum (from -43.2 ± 30.4 to -57.1 ± 33.9;  $p = 0.0228$ ). There was no significant change for posterior corneal elevation. The central elevation varied from 35.5 ± 38.7 to 29.6 ± 34.1, and the minimum elevation varied from -78.4 ± 60.4 to -87.7 ± 54.6 (Table 2).

There was no change in biomechanical parameters of the cornea. The CH varied from 7.7 ± 1.4 to 7.5 ± 1.0 and the CRF varied from 6.3 ± 1.6 to 5.8 ± 1.3. These changes were not statistically significant (Table 3).

**Table 1:** Refractive results (preoperative vs postoperative)

| Parameter       | Pre         | Post        | p-value |
|-----------------|-------------|-------------|---------|
| Mean UDVA       | 1.0         | 0.3         | 0.0001  |
| Mean CDVA       | 0.51        | 0.12        | 0.0001  |
| Keratometry (D) | 50.7 ± 4.2  | 47.5 ± 3.7  | 0.0003  |
| (range)         | (44.5-58.4) | (42.7-54.8) |         |
| Astigmatism (D) | 5.5 ± 3.0   | 3.5 ± 2.5   | 0.0058  |
| (range)         | (0.6-11.4)  | (0.3-11.4)  |         |

CDVA: Corrected distance visual acuity; UDVA: Uncorrected distance visual acuity; logMAR scale

**Table 2:** Tomographic results (preoperative vs postoperative)

| Parameter                | Pre          | Post         | p-value |
|--------------------------|--------------|--------------|---------|
| Anterior elevation (μm)  |              |              |         |
| Central                  | 16.2 ± 23.8  | 8.8 ± 19.7   | 0.0066  |
| Minimum                  | -43.2 ± 30.4 | -57.1 ± 33.9 | 0.0228  |
| Posterior elevation (μm) |              |              |         |
| Central                  | 35.5 ± 38.7  | 29.6 ± 34.1  | NS      |
| Minimum                  | -78.4 ± 60.4 | -87.7 ± 54.6 | NS      |
| Pachymetry (μm)          |              |              |         |
| Central                  | 473.2 ± 43.6 | 477.7 ± 46.4 | NS      |
| Minimum                  | 441.2 ± 48.8 | 455.2 ± 53.4 | 0.0040  |

NS: Not significant

**Table 3:** Biomechanical results (preoperative vs postoperative)

| Parameter          | Pre       | Post      | p-value |
|--------------------|-----------|-----------|---------|
| CRF (mm Hg)        | 6.3 ± 1.6 | 5.8 ± 1.3 | NS      |
| Hysteresis (mm Hg) | 7.7 ± 1.4 | 7.5 ± 1.0 | NS      |

CRF: Corneal resistance factor; NS: Not significant

In one patient, migration of one ICRS toward the incision site was observed on the first postoperative day. It was repositioned, with a security checkpoint at the entrance port. This was the only postoperative complication.

## DISCUSSION

Intrastromal corneal ring segments have been proposed and investigated as an additive surgical procedure for keratoconus correction, which provides an interesting alternative aiming at delaying, if not avoiding, corneal grafting in keratoconus patients.

The purpose of this study was to determine the changes induced by this surgical technique, correlating the results with the refractive, tomographic and biomechanical parameters.

There was regularization of the corneal surface and improvement of visual acuity, both corrected and uncorrected, with reduction of astigmatism and of the K medium. There was an increase of minimum pachymetric values, without any change of the central corneal thickness. No significant change of corneal biomechanical parameters was observed.

Adequate and reliable measurement of anterior segment parameters in keratoconus patients is crucial for the follow-up and surgical planning, especially in cases of ICRS implantation. Nowadays, the Pentacam can be considered as the gold standard for image and data acquisition, as its resolution is 0.1D.

The issue of reliability of results, obtained with the corneal Pentacam, has been raised, both in relation to the value measured and to the variability of the results. The comparison of Pentacam with other methods,<sup>14</sup> such as ultrasonic pachymetry or the Orbscan, showed that the device used in this study provided similar results to those obtained with ultrasonic pachymetry, currently considered the gold standard device for cornea thickness measurement, the only difference being a slight reduction of the values obtained with the Pentacam. A similar result was obtained in our department.<sup>9</sup>

A problem that arises frequently, is the influence of other parameters beyond those obtained by tomography, such as those related to biomechanics. Although the ORA allow a determination of corneal hysteresis and CRF *in vivo*, the clinical application of these data are still not well

understood. For this reason, and because corneal biomechanics in keratoconus is different from normal corneas, we studied the biomechanics in our group of patients to assess its possible modification by the placement of the ICRS.<sup>15</sup>

Complications related to ICRS implantation are uncommon. Kwitko and Severo<sup>16</sup> reported about 20% of complications, while Siganos et al only refer to the need to remove the ring in two cases (7.7% of the total).<sup>12</sup> In our study, only one segment needed to be repositioned and in this case we need to suture the incision, since the segment had migrated towards the incision site. Thus, our complication rate was 5%, which is not significantly different from the result presented by Siganos et al.<sup>12</sup>

There was an overall improvement in visual acuity, both uncorrected and distance corrected. Uncorrected distance visual acuity improved after surgery in all patients, from preoperative values greater than 1.00 to values ranging between 1.00 (1 case—5%) and 0.00 (three cases—15%), with an average value of 0.30. As for distance corrected visual acuity, there was only one case (5%) in which the preoperative value was maintained after surgery. In the remaining, there was improvement from an average of 0.51 preoperatively to an average of 0.12 postoperatively. Six eyes (30%) improved the CDVA to 1.00. These results at 18 months are similar to published literature. It is to be specially noted the almost complete overlap with the results obtained at 6 months by Hellsted et al<sup>17</sup> with Intacs, and those obtained by Siganos et al with the rings of Ferrara.<sup>12</sup>

The average K value reduced from  $50.7 \pm 15.4D$  to  $47.5 \pm 3.66D$ , with a concomitant reduction of mean astigmatism from  $5.5 \pm 2.97D$  to  $3.5 \pm 2.54D$ . The reduction in the average K-value of about 3D and in the average value of astigmatism of 2.0D are of the same order of magnitude of those referred both for Intacs<sup>18</sup> and for Ferrara rings.<sup>12,16</sup>

There are few studies regarding the long-term follow-up after ICRS implantation. Alió et al<sup>19</sup> and Torquetti et al<sup>13</sup> showed results after four and five years respectively, however most studies have relatively short follow-ups, between 6 months and about one year.<sup>16,20-22</sup> It seems that the stability might be reached early, since the comparison of our results with those of Siganos et al<sup>12</sup> suggests that the stabilization of astigmatism should be reached before the 6th month.

It has been recently proposed the use of femtosecond laser as a safe and accurate method for the creation of the intrastromal tunnel.<sup>23</sup> Comparing the results obtained with the intrastromal tunnel created by the laser with our results using a mechanical technique, there is no difference in the incidence of perioperative complications (6% vs 5%).<sup>23</sup> Our results are almost identical to those obtained with the



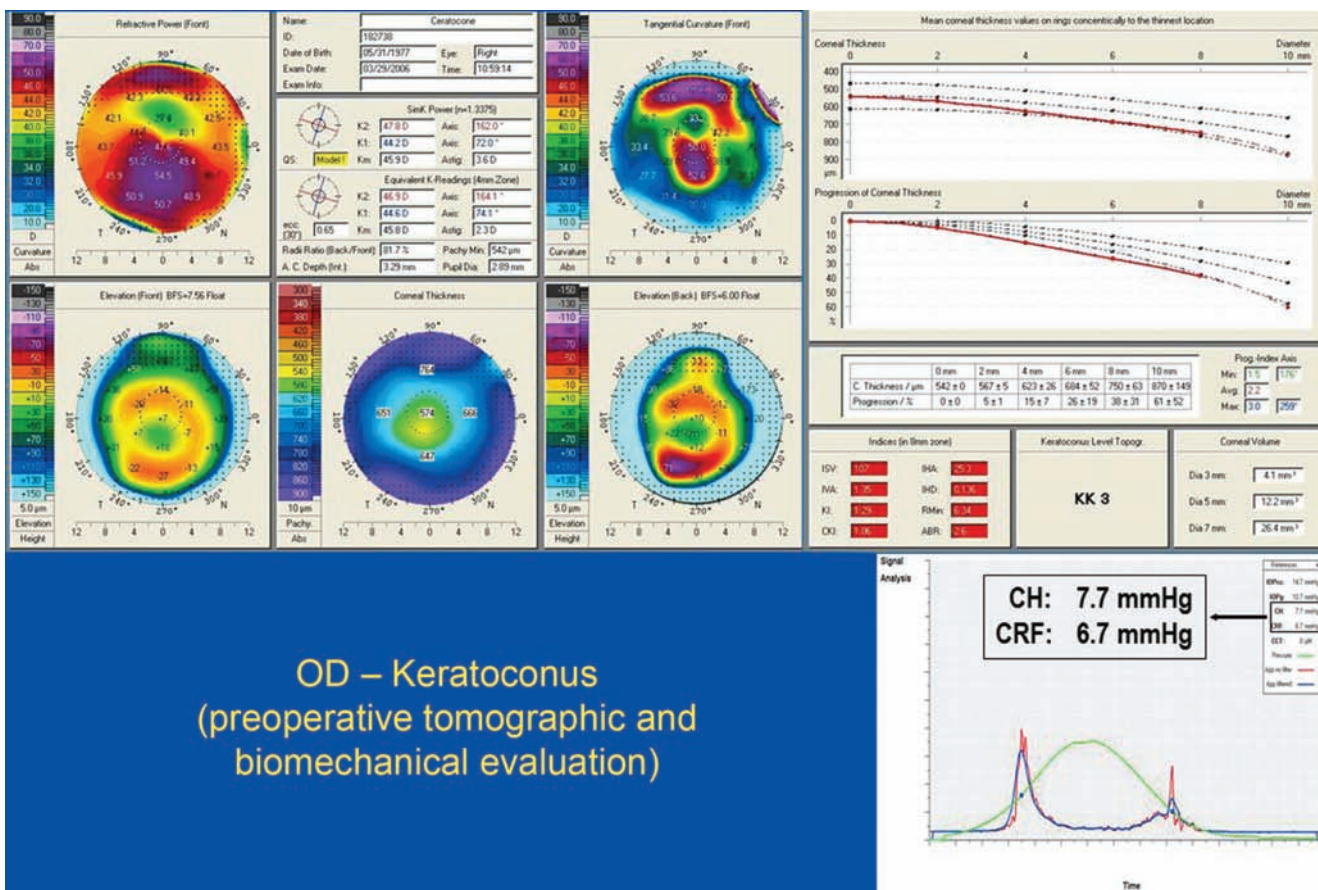


Fig. 1: Preoperative tomographic and biomechanical evaluation of a keratoconus

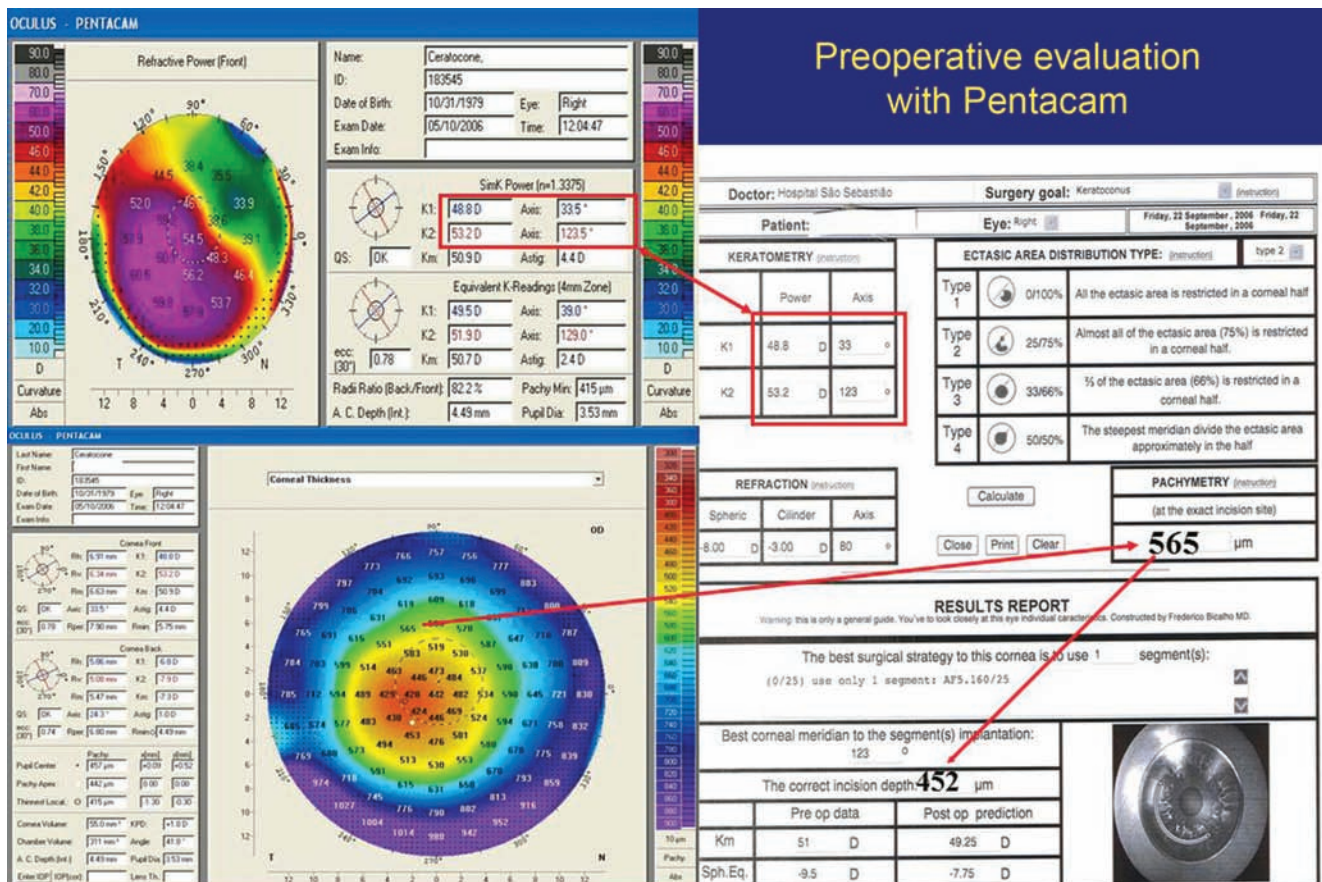


Fig. 2: Preoperative evaluation with Pentacam



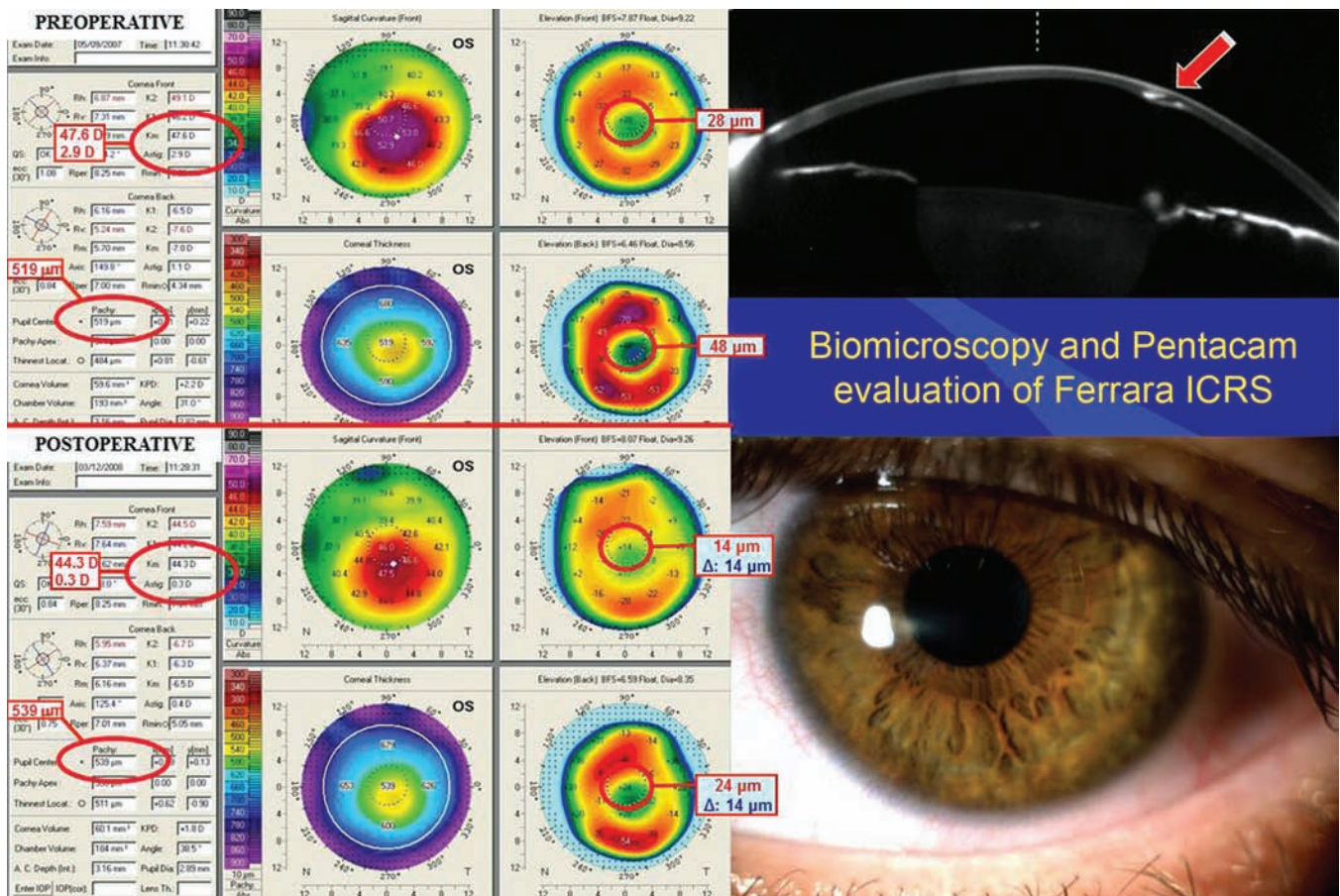


Fig. 3: Biomicroscopy and Pentacam evaluation after Ferrara ICRS implantation

femtosecond laser and using KeraRings, both for the refractive results (reduction of average value of the astigmatism from 4.13D to 2.18D vs a decrease from 5.5 to 3.5D in our study) and topographic results (reduction in mean K from 50.63D to 47.56D vs reduction from 50.7D to 47.5D in our study).<sup>23</sup> Thus, the use of femtosecond laser may not provide better outcomes, but rather an easier and more reproducible technique for the surgeon.

In our study, we found that the mean central corneal thickness did not change after the ring implantation. By contrast, the average minimum pachymetry increased significantly from  $441.2 \pm 48.84 \mu\text{m}$  to  $455.2 \pm 53.39 \mu\text{m}$ . The explanation for these results could be related to the changes of anterior and posterior corneal elevation induced by the rings. It was observed that the posterior elevation is not changed by the surgery; however, there was a significant reduction in the anterior elevation, both the central and minimum. This could, theoretically, be explained by a structural rearrangement of the cornea induced by the intracorneal rings, that gives rise to an increased pachymetry, the central change being less pronounced than that observed at the point of least thickness.

The corneal biomechanics in keratoconus is different from that found in normal corneas, including low values of CRF and hysteresis. In a previous study in our department,

we found a statistically significant difference ( $p < 0.0001$ ) between controls and patients with keratoconus, respectively  $10.8 \pm 1.3$  and  $8.2 \pm 1.3$  mm Hg for hysteresis and  $10.8 \pm 1.1$  and  $7.0 \pm 1.7$  mm Hg for CRF.<sup>15</sup> Dauwe et al,<sup>21</sup> in a study using Intacs and with an average follow-up of 6 months, observed no change in the biomechanical measured values. In our study, although with a different type of ICRS, we also did not observe changes in the biomechanical parameters after a follow-up of 18 months.

In this study, we observed that the improvement in visual acuity after the placement of Ferrara rings was accompanied by marked topographic changes. On the contrary, pachymetric changes were small and no changes in corneal viscoelasticity were evident.

Studies with a larger number of patients and with a longer follow-up are needed to assess the accuracy of presented results.

## REFERENCES

1. Kaya V, Utine CA, Altunsoy M, Oral D, Yilmaz OF. Evaluation of corneal topography with Orbscan II in first-degree relatives of patients with keratoconus. *Cornea* 2008;27:531-34.
2. Wollensak G, Spoerl E, Seiler T. Riboflavin/ultraviolet-A-induced collagen crosslinking for the treatment of keratoconus. *Am J Ophthalmol* 2003;135:620-27.

3. Wollensak G. Crosslinking treatment of progressive keratoconus: New hope. *Curr Opin Ophthalmol* 2006;17:356-60.
4. Grewal DS, Brar GS, Jain R, Sood V, Singla M, Grewal SP. Corneal collagen crosslinking using riboflavin and ultraviolet—a light for keratoconus: One-year analysis using Scheimpflug imaging. *J Cataract Refract Surg* 2009;35:425-32.
5. Nosé W, Neves RA, Schanzlin DJ, Belfort R Jr. Intrastromal corneal ring: One-year results of first implants in humans: A preliminary nonfunctional eye study. *Refract Corneal Surg* 1993;9:452-58.
6. Torquetti L, Ferrara P. Intrastromal corneal ring segment implantation for ectasia after refractive surgery. *J Cataract Refract Surg* 2010;36:986-90.
7. Ertan A, Colin J. Intracorneal rings for keratoconus and keratectasia. *J Cataract Refract Surg* 2007;33:1303-14.
8. Ferrara P, Torquetti L. Clinical outcomes after implantation of a new intrastromal corneal ring with a 210 degree arc length. *J Cataract Refract Surg* 2009;35:1604-08.
9. Salgado-Borges J, Monteiro M, Costa-Ferreira C, Dias L, Ferrara P. Corneal tomographic and biomechanical changes after Ferrara intrastromal rings for keratoconus correction. In: Abstracts of the 13th ESCRS Winter Meeting. Rome: ESCRS 2009;30.
10. Asbell PA, Ucakhan O. Long-term follow-up of Intacs from a single center. *J Cataract Refract Surg* 2001;27:1456-68.
11. Colin J, Velou S. Implantation of Intacs and a refractive intraocular lens to correct keratoconus. *J Cataract Refract Surg* 2003;29:832-34.
12. Siganos D, Ferrara P, Chatzinikolas K, Bessis N, Papastergiou G. Ferrara intrastromal corneal rings for the correction of keratoconus. *J Cataract Refract Surg* 2002;28:1947-51.
13. Torquetti L, Berbel RF, Ferrara P. Long-term follow-up of intrastromal corneal ring segments in keratoconus. *J Cataract Refract Surg* 2009;35:1768-73.
14. Khoramnia R, Rabsilber TM, Auffarth GU. Central and peripheral pachymetry measurements according to age using the Pentacam rotating Scheimpflug camera. *J Cataract Refract Surg* 2007;33: 830-36.
15. Soares R, Ferreira C, Dias L, Monteiro JG, Salgado-Borges J. Biomecânica da córnea no ceratocone. Abstract of the 49th Congress of the SPO. Évora, Portugal: SPO 2006, CL17.
16. Kwirtko S, Severo NS. Ferrara intracorneal ring segments for keratoconus. *J Cataract Refract Surg* 2004;30:812-20.
17. Hellstedt T, Mäkelä J, Uusitalo R, Emre S, Uusitalo R. Treating keratoconus with Intacs corneal ring segments. *J Refract Surg* 2005;21:236-46.
18. Colin J, Cochener B, Savary G, Malet F, Holmes-Higgin D. Intacs inserts for treating keratoconus. One-year results. *Ophthalmology* 2001;108:1409-14.
19. Alió JL, Shabayek MH, Artola A. Intracorneal ring segments for keratoconus correction: A long-term follow-up. *J Cataract Refract Surg* 2006;32:978-85.
20. Alió JL, Shabayek MH, Belda JI, Correas P, Feijoo ED. Analysis of results related to good and bad outcomes of Intacs implantation for keratoconus correction. *J Cataract Refract Surg* 2006;32: 756-61.
21. Dauwe C, Touboul D, Roberts CJ, et al. Biomechanical and morphological corneal response to placement of intrastromal corneal ring segments for keratoconus. *J Cataract Refract Surg* 2009;35:1761-67.
22. Boxer Wachler BS, Chandra NS, Chou B, Korn TS, Nepomuceno R, Christie JP. Intacs for keratoconus. *Ophthalmology* 2003;110:1031-40.
23. Coskunseven E, Kymionis GD, Tsiklis NS, et al. One-year results of intrastromal corneal ring segment implantation (KeraRing) using femtosecond laser in patients with keratoconus. *Am J Ophthalmol* 2008;145:775-79.

## ABOUT THE AUTHORS

### José M Salgado-Borges (Corresponding Author)

Professor and Ophthalmologist, Department of Ophthalmology, CHEDV and UFP, Porto, Portugal, e-mail: salgadoborges@hotmail.com

### Cláudia Costa-Ferreira

Ophthalmologist, Department of Ophthalmology, CHEDV, Porto Portugal

### Manuel Monteiro

Professor and Ophthalmologist, Department of Ophthalmology Clínica Oftalmológica das Antas, Porto, Portugal

### José Guilherme-Monteiro

Professor and Ophthalmologist, Department of Ophthalmology CHEDV, Porto, Portugal

### Leonardo Torquetti

Ophthalmologist, Department of Ophthalmology, Ferrara Eye Clinic Minas Gerais, Brazil

### Paulo Ferrara

Professor and Ophthalmologist, Department of Ophthalmology Ferrara Eye Clinic, Minas Gerais, Brazil

### Renato Ambrósio Jr

Professor and Ophthalmologist, Corneal Tomography and Biomechanics Study Group, Rio de Janeiro, Brazil