

# Intrastromal corneal ring segment implantation to correct astigmatism after penetrating keratoplasty

Sandro Coscarelli, MD, Guilherme Ferrara, MD, Jose F. Alfonso, MD, PhD, Paulo Ferrara, MD, PhD, Jesús Merayo-Llodes, MD, PhD, Luana P.N. Araújo, MD, Aydano P. Machado, PhD, João Marcelo Lyra, MD, PhD, Leonardo Torquetti, MD, PhD

**PURPOSE:** To evaluate the clinical outcomes of implantation of Ferrara intrastromal corneal ring segments (ICRS) in patients with astigmatism after penetrating keratoplasty (PKP).

**SETTING:** Private clinic, Belo Horizonte, Brazil.

**DESIGN:** Retrospective consecutive case series.

**METHODS:** Chart records of post-PKP patients who had ICRS implantation from May 2005 to September 2009 were retrospectively reviewed. The following parameters were studied: corrected distance visual acuity (CDVA), keratometry (K) values, spherical equivalent (SE), spherical refractive error, corneal topographic astigmatism, minimum K, and maximum K.

**RESULTS:** The study evaluated 59 eyes (54 patients). The mean CDVA (logMAR) improved from  $0.45 \pm 0.17$  (SD) (range 0.18 to 1.00) to  $0.30 \pm 0.17$  (range 0.00 to 1.00). The mean SE was  $-6.34 \pm 3.40$  diopters (D) (range 0.37 to  $-16.50$  D) preoperatively and  $-2.66 \pm 2.52$  D (range 0.87 to  $-10.50$  D) postoperatively. The mean spherical refractive error decreased from  $-7.10 \pm 3.07$  D (range 2.15 to 16.68 D) preoperatively to  $-3.46 \pm 2.05$  D (range 0.88 to 10.79 D) postoperatively. No patient lost visual acuity. The mean corneal topographic astigmatism decreased from  $3.37 \pm 1.51$  D preoperatively to  $1.69 \pm 1.04$  D postoperatively. The mean maximum K value decreased from  $48.09 \pm 2.56$  D to  $44.17 \pm 2.67$  D and the mean minimum K value, from  $44.90 \pm 2.54$  D to  $42.46 \pm 2.63$  D. All changes were statistically significant ( $P < .0001$ ).

**CONCLUSION:** Intrastromal corneal ring segments effectively reduced corneal cylinder in patients with astigmatism after PKP.

**Financial Disclosure:** Drs. Ferrara and Merayo-Llodes have proprietary interest in the Ferrara ring. Drs. Coscarelli, Torquetti, and Alfonso have no financial or proprietary interest in any material or method mentioned.

*J Cataract Refract Surg* 2012; 38:1006–1013 © 2012 ASCRS and ESCRS

The postoperative astigmatism associated with penetrating keratoplasty (PKP) is a common condition in clinical practice. The reason for this could be related to factors inherent to the receptor, such as previous corneal trauma or keratoconus.<sup>1</sup> Additional contributing factors may include the trephination technique, inadequate fixation of the eye during surgery with compression or deformation of the ocular globe, the suture technique, and postoperative issues such as the patient's age and receptor corneal disease, time on topical corticosteroids, and early suture removal.<sup>2</sup>

Previous studies<sup>2–4</sup> report several risk factors that may increase the incidence of post-PKP astigmatism and its management. Contact lenses are a better choice than spectacles to correct astigmatism because they provide better quality of vision.<sup>5,6</sup> Moreover, the corrected distance visual acuity (CDVA) with contact lenses is usually better than with spectacles in this type of astigmatism. When optical methods fail to achieve satisfactory visual rehabilitation, surgical treatment may be necessary. Whereas some authors have published that incisions and wedge resection of the cornea could be useful to correct the

astigmatism,<sup>7-9</sup> other authors report that laser in situ keratomileusis (LASIK)<sup>10,11</sup> or the implantation of toric phakic intraocular lenses (pIOLs) could achieve better and more predictable results.<sup>12,13</sup>

In the present study, we evaluated the use of intrastromal corneal ring segments (ICRS) as an alternative surgical option for the treatment of astigmatism in patients who had PKP for keratoconus, bullous keratopathy, radial keratotomy (RK), post-LASIK ectasia, or stromal scarring. The outcome analysis comprised the CDVA, spherical equivalent (SE), refractive error, corneal topographic astigmatism, and minimum and maximum keratometry (K) values. To our knowledge, this study has the largest sample of patients with ICRS implantation to correct post-PKP astigmatism in the literature.

## PATIENTS AND METHODS

This retrospective study included consecutive post-PKP patients who had ICRS implantation (Ferrara ring, Ferrara e Hijos) from May 2005 to September 2009 to correct residual astigmatism. All patients were informed about the possible intraoperative and postoperative complications and gave written informed consent in accordance with institutional guidelines and the Declaration of Helsinki.

Inclusion criteria were a clear and transparent corneal graft, a minimum of 2.50 diopters (D) and a maximum of 8.00 D of astigmatism, and contact lens intolerance. All patients had at least 2 years of follow-up after PKP before ICRS implantation. Patients who did not meet the inclusion criteria were not evaluated in this study.

## Surgical Technique

The same surgeon (S.C.) performed all surgeries using a manual technique as previously described.<sup>14</sup> The surgery was performed using topical anesthesia after miosis was achieved with pilocarpine 2.0%. The visual axis was marked by pressing a Sinskey hook on the central corneal epithelium while asking the patient to fixate on the corneal light reflex of the microscope light. Using a marker tinted with gentian violet, a 5.0 mm optical zone and incision site were aligned to the desired axis in which the incision would be made. This incision site was always at the steepest topographic axis of the cornea given by the topographer.

Submitted: May 23, 2011.

Final revision submitted: November 18, 2011.

Accepted: December 5, 2011.

From Ennio Coscarelli Eye Clinic (Coscarelli), Paulo Ferrara Eye Clinic (G. Ferrara, P. Ferrara, Torquetti), Belo Horizonte and Brazilian Study Group of Artificial Intelligence and Cornea (Araújo, Machado, Lyra, Torquetti), Maceió, Brazil; Fernandez-Vega Eye Institute (Alfonso, Merayo-Llones), Oviedo, Spain.

Corresponding author: Guilherme Ferrara, MD, Avenida Brasil, 1312 – Santa Efigenia – Belo Horizonte, MG 30140-001, Brazil. E-mail: [guilherme@ferraring.com.br](mailto:guilherme@ferraring.com.br).

A square diamond blade was set at 80% of corneal thickness at the incision site, and this blade was used to make the incision. A pocket was formed in each side of the incision using a stromal spreader. Two (clockwise and counterclockwise) 270-degree semicircular dissecting spatulas were consecutively inserted through the incision and gently pushed with quick rotary back-and-forth tunneling movements. After channel creation, the ring segments were inserted using a modified McPherson forceps. The rings were properly positioned with the aid of a Sinskey hook.

## Postoperative Regimen and Assessment

The postoperative regimen consisted of tobramycin 0.3% and dexamethasone 0.1% eyedrops 4 times a day for 1 week, after which the dose was tapered over 3 weeks. In addition, patients received topical lubricants 4 times a day for at least 3 months.

Postoperative examinations were performed at 1 and 7 days, after 1 and 6 months, and then every year. Measurement of CDVA, slitlamp evaluation, refraction, corneal topography, funduscopy, and tonometry were performed at each control visit. Visual acuity was determined on a Snellen chart and then converted to logMAR notation. The K values were obtained by corneal topography (CT4000 Corneal Topographer, Eyeteck, Inc.).

To evaluate the CDVA, refractive error, and corneal topographic astigmatism, the nonparametric Mann-Whitney test was used because at least 1 datum from the sample did not have a Gaussian distribution. The SE was corrected by Welch transformation because of significant difference between 2 standard deviations (SDs).

## Analysis of Astigmatism

The astigmatism results were analyzed arithmetically (nonvector analysis) and with regard to the cylindrical axis using vector analysis. Although empirical changes in cylinders are commonly reported, they do not accurately reflect the true nature of the change in cylinder. Cylinders have a magnitude and an axis, which are related to the spherical power.<sup>15</sup> To take into account all 3 components, the data in this study were transformed into Cartesian coordinates (ie,  $x$  and  $y$  coordinates) to allow mathematic analyses. The result in the Cartesian coordinate form was then reconverted into polar coordinates (sphere, cylinder, axis). To distinguish the mean value of the cylinder calculated in this manner, the term *centroid* has been proposed.<sup>16</sup>

Refractions before and 12 months after ICRS insertion were assessed for astigmatism using the power vector method.<sup>17</sup> Any spherocylindrical refractive error was expressed by 3 dioptric powers: M, J0, J45, with M being the aspheric lens equal to the SE of the given refractive error and J0 and J45 being 2 Jackson cross-cylinders equivalent to the conventional cylinders. These numbers are the coordinates of a point in a 3-dimensional dioptric space, being the power vector from the origin of this space to the point (M, J0, J45). Thus, the length of the vector is a measure of the overall blurring strength of the spherocylindrical refractive error. Changes in refractive error induced by the surgery were computed by the ordinary rules of vector extraction.

The target astigmatism is the intended astigmatic correction in each individual eye. The ideal target astigmatism was zero (ie, intention to correct the full magnitude of the cylinder).

**Statistical Analysis**

Data reported here are from the 12-month examination after ICRS implantation. Statistical analysis included the Student *t* test, Welch transformation, and Mann-Whitney nonparametric test and was performed using Instat for Macintosh software (version 3.1a, Graphpad Software). Vectorial analysis was performed using SigmaPlot software (SPSS Inc.). Internet-Based Refractive Analysis software (Zubisoft GmbH) was used for clinical outcomes analysis.

**RESULTS**

This study included 59 eyes of 54 patients. The mean age of the 28 women (51.85%) and 26 men (48.14%) was 36.01 years ± 11.02 (SD) (range 19 to 72 years). The indications for PKP were keratoconus in 49 eyes, post-LASIK ectasia in 5 eyes, progressive hyperopia secondary to RK in 2 eyes, stromal scarring in 2 eyes, and bullous keratopathy in 1 eye. Forty-nine patients had a single eye treatment, whereas 5 patients had both eyes treated.

All patients completed at least 1 year of follow-up. The mean follow-up was 14 months.

Table 1 shows the preoperative and last follow-up examination data. The preoperative corneal astigmatism ranged from 3.00 to 5.00 D. Figures 1 and 2 show the preoperative and postoperative CDVA. No patient lost visual acuity. Of the patients, 28 (47.4%) gained 2 or more lines of CDVA (Figure 3). The

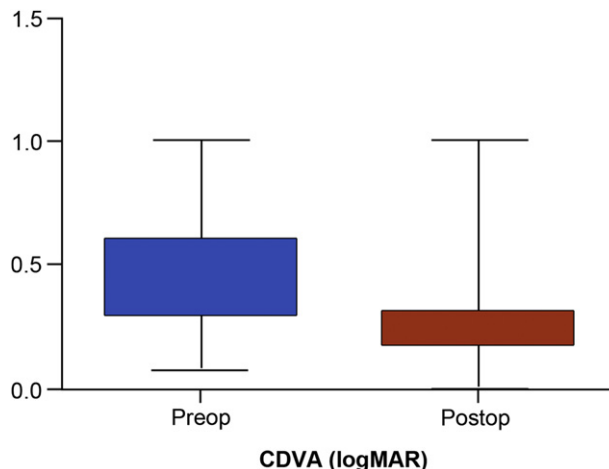


Figure 1. The CDVA (logMAR) before and after the ICRS implantation (unpaired *t* test) (CDVA = corrected distance visual acuity).

improvements in CDVA, SE, and refractive error were statistically significant (*P* < .0001).

**Intended Correction**

Regarding the predictability of the postoperative SE, 43 eyes (72.8%) presented with undercorrection and 9 (15.2%) with overcorrection. There was concordance between the attempted refraction and achieved refraction in 7 eyes (13.0%) (Figure 4).

The decrease in the mean corneal topographic astigmatism at 3.0 mm from preoperatively to postoperatively was statistically significant (*P* < .0001). Most eyes had more than 3.0 D of refractive astigmatism preoperatively (Figure 5). Approximately half the eyes remained with more than 3.00 D of refractive astigmatism postoperatively; the rest had less than 3.00 D (Figure 6). The decrease in K values from preoperatively to postoperatively was

Parameter	Preoperative	Postoperative	<i>P</i> Value
Eyes (n)	59	—	—
Patients (n)	54	—	—
Sex (n)			
Male	26	—	—
Female	28	—	—
Mean age (y)	36.01 ± 11.02	—	—
Mean follow-up (mo)	14	—	—
CDVA (logMAR)			.001
Mean ± SD	0.45 ± 0.17	0.30 ± 0.17	
Range	0.18, 1.00	0.00, 1.00	
SE (D)			.001
Mean ± SD	-6.34 ± 3.40	-2.66 ± 2.52	
Range	0.37, -16.50	0.87, -10.50	
Spherical refractive error (D)			.001
Mean ± SD	-7.10 ± 3.07	-3.46 ± 2.05	
Range	2.15 to 16.68	0.88 to 10.79	
Mean TA at 3.0 mm (D)	3.37 ± 1.51	1.69 ± 1.04	.001
Mean maximum K (D)	48.09 ± 2.56	44.17 ± 2.67	.001
Mean minimum K (D)	44.90 ± 2.54	42.46 ± 2.63	.001

CDVA = corrected distance visual acuity; K = keratometry; SE = spherical equivalent; TA = topographic astigmatism

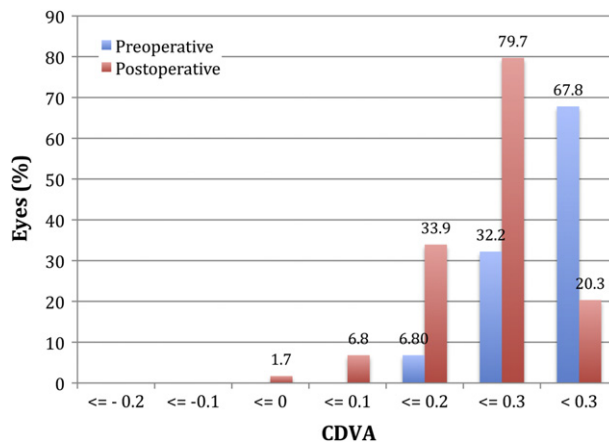


Figure 2. Preoperative and postoperative CDVA (logMAR) (CDVA = corrected distance visual acuity).

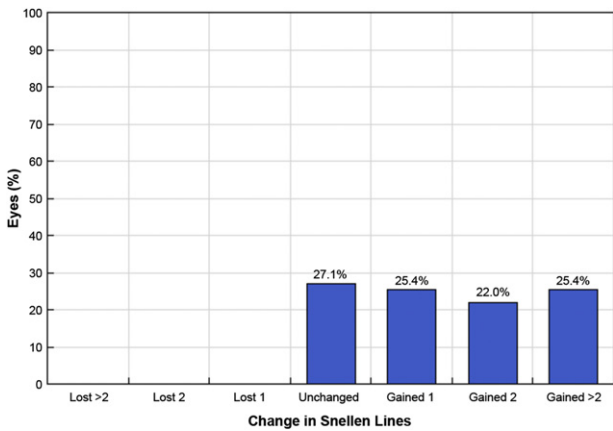


Figure 3. Lines of CDVA lost and gained.

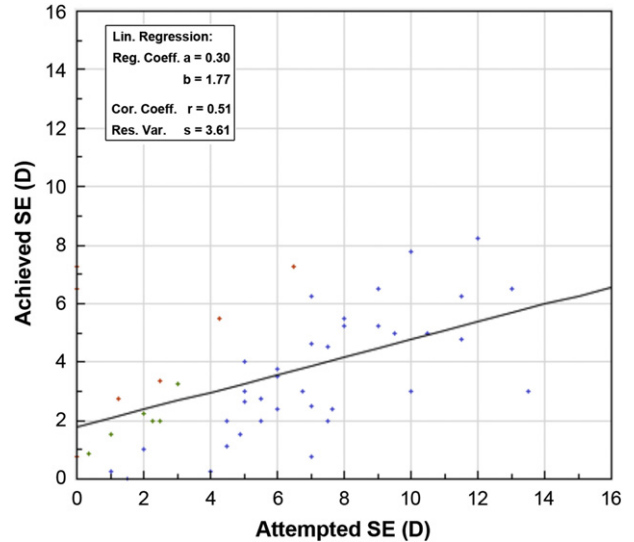


Figure 4. Predictability of SE correction. The blue dots represent undercorrection, the green dots represent full correction, and the red dots represent overcorrection (Cor. = correlation; Coeff. = coefficient; Lin. = linear; SE = spherical equivalent; Res. Var. = response variable).

statistically significant ( $P < .0001$ ) (Table 1). Vectorial analysis showed that most eyes had a statistically significant reduction in spherocylinder refractive error (Figure 7).

**Double-Angle Plot**

Figure 8 shows the double-angle plots of the individual cylinders, providing an overview of the cylinder magnitude (diopter) and axis (degree) of each data point. The radius from the center of the plot to each individual point represents the magnitude of the cylinder. After ICRS implantation, the refractive astigmatism centroid was 1.00 D closer to zero and the SD of the astigmatism was reduced by a factor of

1.66 (3.83 D/2.31 D). The relocation of the centroid closer to the origin and the contraction of the ellipse on the doubled-angle plots show the amount of improvement.

Figure 9 shows the doubled-angle plot of the preoperative and postoperative keratometric astigmatism. Although there was a reduction in the mean keratometric astigmatism, it was considerably less than the reduction in refractive astigmatism.

There were no vision-threatening complications. The ICRS were deeply implanted in all eyes (Figure 10). In 3 eyes (5%), the surgical procedure was interrupted due to dehiscence of the inner layers of corneal transplantation, even 2 years after transplantation.

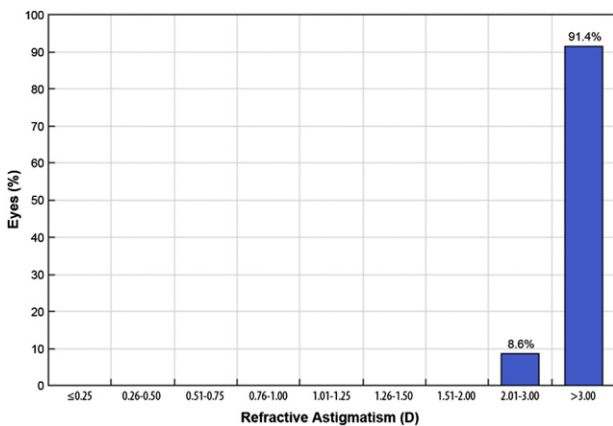


Figure 5. Preoperative refractive astigmatism.

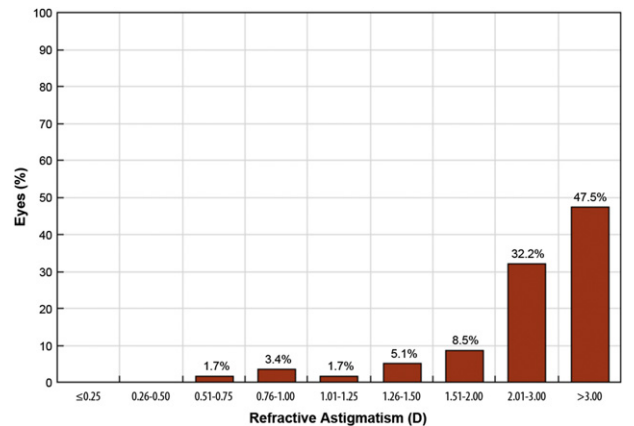
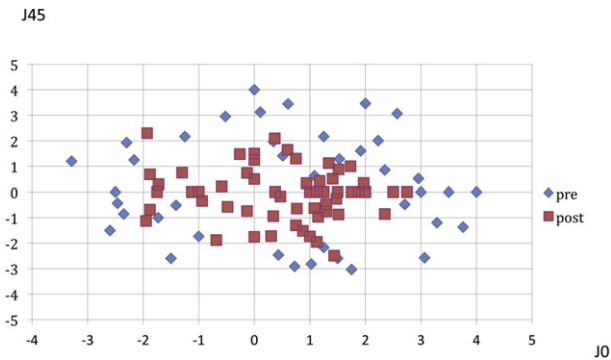


Figure 6. Postoperative refractive astigmatism.

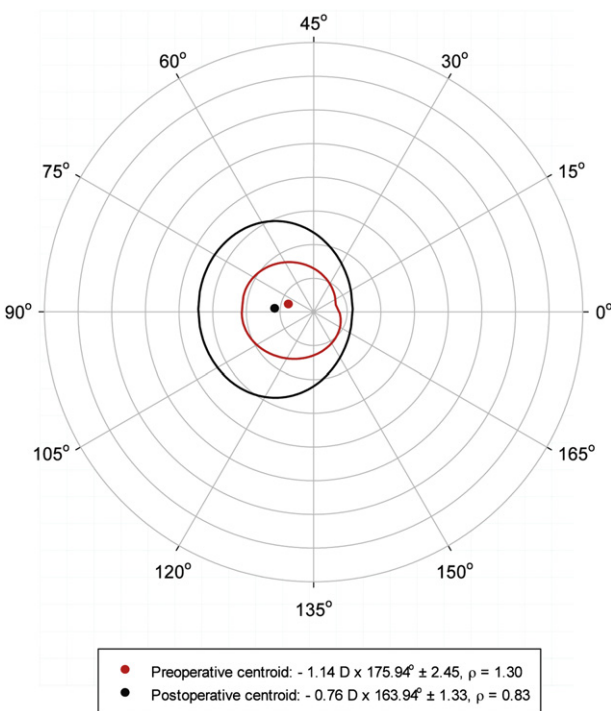




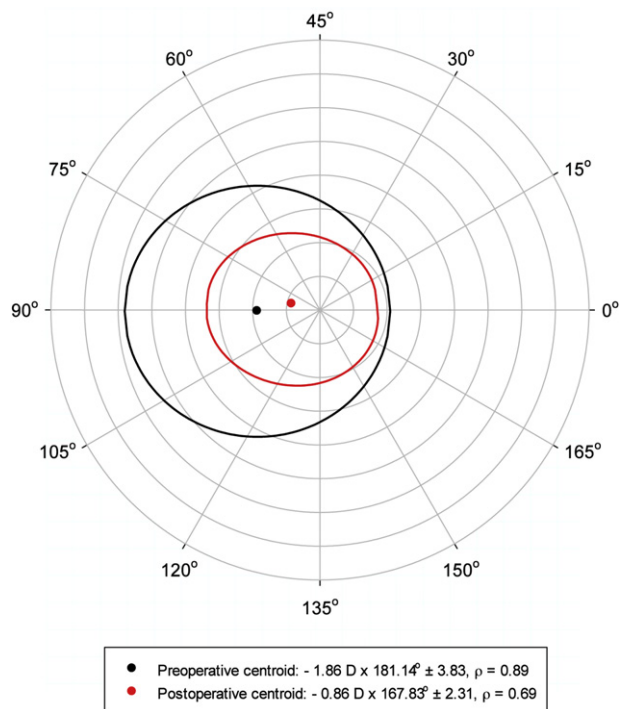
**Figure 7.** Astigmatic vectors ( $J_0$  and  $J_{45}$ ) before and 12 months after ICRS implantation. The more central location (0,0) of postoperative data represents the reduction of preoperative astigmatism by the implantation of the ICRS.

**DISCUSSION**

Post-PKP residual astigmatism and refractive error are frequently observed,<sup>11,18</sup> and their management may be a challenge for anterior segment surgeons. In this retrospective study, we evaluated 59 eyes of 49 patients who had ICRS implantation to correct irregular astigmatism after previous PKP. Despite proper wound healing and good anatomic results, high and/or irregular astigmatism can preclude satisfactory vision in these patients.



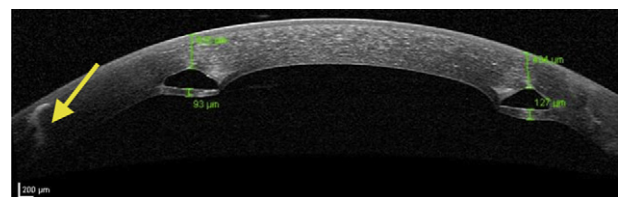
**Figure 9.** Double-angle plot of keratometric astigmatism.



**Figure 8.** Double-angle plot of refractive astigmatism. Individual cylinders demonstrate the cylinder magnitude (D) and axis (degrees). The radius from the center of the plot to each individual point represents the magnitude of the cylinder.

Many factors inherent to the patient, host cornea, surgical technique, and postoperative management may influence the astigmatism.<sup>2</sup> Peripheral disorders, such as keratoconus,<sup>1</sup> can persist on the corneal host and cause irregular astigmatism. This cause possibly explains the high prevalence of keratoconus patients in our study. Although contact lenses and excimer laser refractive surgery are viable options in this group of eyes,<sup>19-21</sup> contact lens-related problems, such as dry eye, neovascularization, and rejection of donor cornea, must be considered,<sup>22</sup> as well as contraindications to PRK or LASIK because of high ametropia, low baseline corneal thickness, and young age that make these patients unsuitable for corneal laser refractive surgery.<sup>23</sup>

The visual outcomes in our study were satisfactory. The CDVA was unchanged in 16 eyes (27.2%)



**Figure 10.** Anterior segment optical coherence tomography shows the ICRS deeply implanted in the cornea stroma and graft-host interface (yellow arrow).

postoperatively, whereas 43 eyes (72.8%) improved at least 1 line. The mean SE value decreased from  $-6.34 \pm 3.40$  D to  $-2.66 \pm 2.52$  D, and the K values also decreased, improving the corneal irregularity.

Alfonso et al.<sup>24</sup> and Morshirfar et al.<sup>12</sup> evaluated the results of pIOL implantation in young patients for the correction of refractive errors after PKP and found safe, predictable, and stable visual and refractive outcomes. Alfonso et al.<sup>24</sup> describe the efficacy, predictability, and safety of Implantable Collamer Lens posterior chamber pIOL implantation for the correction of post-PKP refractive error in 15 eyes of 15 patients; there was a large reduction in the refractive error and CDVA improvement. The postoperative CDVA was 20/40 or better in 12 eyes (80%) and 20/25 in 6 eyes (40%). No eye lost more than 1 line of acuity, 2 eyes gained 1 line, and 5 eyes gained more than 2 lines; 8 eyes were unchanged. Morshirfar et al.<sup>12</sup> evaluated the Artisan iris-supported pIOL to treat high myopia after PKP in 2 patients; there was improvement in uncorrected distance visual acuity and CDVA and no significant endothelial cell density loss 6 months postoperatively.

Our findings are in agreement with results in other studies.<sup>25-27</sup> In a case report, Coskunseven et al.<sup>25</sup> advocate the use of ICRS, a minimally invasive procedure, to correct high astigmatism after PKP. According to Coskunseven et al., eyes with thin corneal grafts and recurrent keratoconus are unsuitable for laser refractive corrections because of the possibility of postoperative complications. In addition, Arriola-Villalobos et al.,<sup>5</sup> in a series of 9 patients, found that ICRS implantation improved the CDVA in all eyes and decreased the topographic mean, minimum, and maximum K values. They conclude that ICRS implantation might be a good surgical choice to correct high astigmatism after PKP and yields good visual, refractive, and topographic outcomes.

Chang and Hardten<sup>27</sup> recommend that ICRS implantation after PKP not be performed until at least 1 year after transplantation and at least 3 months after suture removal. We proceeded as Arriola-Villalobos et al.<sup>5</sup> suggest; that is, we waited at least 2 years after corneal transplantation and a minimum of 6 months after suture removal to avoid damaging the interface by the traction generated by the dissectors used during surgery in the manual technique.

The use of Ferrara ICRS with a 5.0 mm optical zone has 2 advantages over the use of larger optical zone ICRS. First, the central cornea flattening is theoretically greater because the refractive outcome is inversely proportional to the diameter of the segment.<sup>28</sup> The second benefit is that a small diameter ensures greater distance between the rings and the graft-host junction. This reduces the risk for interface dehiscence or

vascularization of the stromal channel by vessels extending from the limbus and host cornea. Thus, in patients with a corneal transplant with a diameter of 7.5 mm or smaller, the ICRS with larger optical zones (6.0 or 7.0 mm) should not be used because the segments would be very close to the graft-host junction. Potential disadvantages of ICRS with a small optical zone are halos and glare. Some patients, especially those with large pupil diameters in dim-light conditions, occasionally report halos and glare.

All patients had PKP performed by the same surgeon (S.C.), who always used a discrepancy of 0.50 mm in trephination between the donor graft (8.0 mm) and the host (7.5 mm). Because the Ferrara ICRS is placed at a 5.0 mm optical zone, it is always located far from the graft-host junction, which makes the procedure safer for small-optical-zone ICRS. However, in cases of small trephinations or decentered grafts, care must be taken to avoid excessive torque, which could open the previous keratoplasty wound, thus requiring sutures and postponing ICRS implantation. In our study, ICRS implantation had to be postponed in 5% of cases (3/59 eyes) because wound dehiscence occurred during dissection. All patients had at least 2 years of follow-up after PKP, which indicates that in some cases the graft-host interface strength can be permanently reduced. This may be related to the depth (too shallow or too deep) of the passage of the 10-0 needle during the keratoplasty and early removal of sutures. Tunnel creation using the femtosecond laser in these cases could not only facilitate the surgical procedure but also prevent this type of complication.<sup>26,29</sup>

Implantation of ICRS after PKP may yield results different than those when the technique is used for keratoconus treatment. Keratoconic corneas are thinner and more elastic than healthy corneas, whereas corneas that had PKP are more rigid, with normal thickness and elasticity. Theoretically, this could explain why 73% of eyes presented with undercorrection and there was a low concordance between the attempted refraction and the achieved refraction. The nomogram of the Ferrara ICRS is designed for keratoconus treatment; thus, the ring thickness should be adjusted when using ICRS for post-keratoplasty cases. This means that thicker segments should be implanted in post-PKP patients given the same K values as in keratoconus patients. The main purpose of ICRS implantation is to regularize the corneal surface and improve visual acuity; the refraction reduction after the surgery could be considered a secondary goal.

There are several potential advantages of ICRS implantation over other surgical techniques in eyes with high astigmatism after PKP. First, ICRS implantation avoids excimer laser treatment, eliminating

central corneal wound healing, which could be unsatisfactory in post-PKP corneas. This leaves the optical center of the cornea untouched, enhancing refractive outcomes. Second, the technique is reversible in cases of unsatisfactory refractive or clinical outcomes. Third, adjustment can be performed using thinner or thicker rings. In cases of unexpected corneal shape changes, 1 segment can be removed or exchanged. Fourth, it avoids the complications of intraocular surgery.

The results in our study suggested that ICRS implantation is a promising treatment for post-PKP astigmatism, especially in eyes with thin and irregular corneas. Long-term randomized comparative prospective studies are needed to better evaluate this technique as a treatment for irregular astigmatism in post-PKP patients.

#### WHAT WAS KNOWN

- Surgical treatments such as wedge resection of the cornea, LASIK, and pIOL implantation are often necessary to manage high astigmatism after PKP when nonsurgical methods fail to achieve satisfactory visual acuity.
- Intrastromal corneal ring segment implantation for the treatment of post-PKP astigmatism has been described in a case report and a 9-patient case series.

#### WHAT THIS PAPER ADDS

- In a larger clinical series, ICRS implantation improved CDVA in 73% of eyes and produced significant reduction in topographic astigmatism. Dehiscence of the graft-host junction with mechanical dissection occurred in 5% of eyes.

#### REFERENCES

1. Lim L, Pesudovs K, Goggin M, Coster DJ. Late onset post-keratoplasty astigmatism in patients with keratoconus. *Br J Ophthalmol* 2004; 88:371–376. Available at: <http://www.ncbi.nlm.nih.gov/pmc/articles/PMC1772053/pdf/bjo08800371.pdf>. Accessed January 28, 2012
2. Barraquer RI, Álvarez de Toledo JP, Álvarez Fisher M, Martínez Grau G. Prevención y tratamiento del astigmatismo en queratoplastia penetrante. *Ann Ophthalmol* 2002; 10:69–80. Available at: [http://www.nexusediciones.com/pdf/ao2002\\_2/of-10-2-003.pdf](http://www.nexusediciones.com/pdf/ao2002_2/of-10-2-003.pdf). Accessed January 28, 2012
3. Landau D, Siganos CS, Mechoulam H, Solomon A, Frucht-Pery J. Astigmatism after mersilene and nylon suture use for penetrating keratoplasty. *Cornea* 2006; 25:691–694
4. Alvarez de Toledo J, de la Paz MF, Barraquer RI, Barraquer J. Long-term progression of astigmatism after penetrating keratoplasty for keratoconus; evidence of late recurrence. *Cornea* 2003; 22:317–323
5. Arriola-Villalobos P, Días-Valle D, Güel JL, Iradier-Urrutia MT, Jiménez-Alfaro I, Cuiña-Sardiña R, Benítez-del-Castillo JM. Intrastromal corneal ring segment implantation for high astigmatism after penetrating keratoplasty. *J Cataract Refract Surg* 2009; 35:1878–1884
6. Price FW Jr, Whitson WE, Marks RG. Progression of visual acuity after penetrating keratoplasty. *Ophthalmology* 1991; 98:1177–1185
7. Burillon C, Durand L, Hachmanian KF. La resection cuneiforme, traitement correctif des astigmatismes corneens geants [Wedge resection, corrective treatment of giant corneal astigmatism]. *J Fr Ophtalmol* 1989; 12:447–453
8. Saragoussi JJ, Abenhaim A, Pouliquen Y. Resultats des incisions transverses dans la correction chirurgicale des forts astigmatismes post-keratoplastie [Results of transverse incisions in surgical correction of severe post-keratoplasty astigmatism]. *J Fr Ophtalmol* 1990; 13:492–499
9. Coscarelli SA, Figueiredo P, Ramos Miranda MDF. Delaminação límbica: uma nova técnica para correção de astigmatismo pós-transplante [Limbal delamination: a new technique for postkeratoplasty astigmatism correction]. *Arq Bras Oftalmol* 2003; 66:189–192. Available at: <http://www.scielo.br/pdf/abo/v66n2/15472.pdf>. Accessed January 28, 2012
10. Aguilar-Montes G, Pérez-Balbuena L, Naranjo-Tackman R. Manejo quirúrgico con técnica de lasik en la corrección del astigmatismo miópico secundario a transplante corneal [Lasik technique for myopic astigmatism correction after corneal transplantation]. *Rev Mex Oftalmol* 2000; 74:221–236
11. Campos M, Hertzog L, Garbus J, Lee M, McDonnell PJ. Photorefractive keratectomy for severe postkeratoplasty astigmatism. *Am J Ophthalmol* 1992; 114:429–436
12. Moshirfar M, Barsam CA, Parker JW. Implantation of an Artisan phakic intraocular lens for the correction of high myopia after penetrating keratoplasty. *J Cataract Refract Surg* 2004; 30:1578–1581
13. Moshirfar M, Grégoire FJ, Mirzaian G, Whitehead GF, Kang PC. Use of Verisyse iris-supported phakic intraocular lens for myopia in keratoconic patients. *J Cataract Refract Surg* 2006; 32:1227–1232
14. Torquetti L, Berbel RF, Ferrara P. Long-term follow-up of intrastromal corneal ring segments in keratoconus. *J Cataract Refract Surg* 2009; 35:1768–1773
15. Bennett AG, Rabbetts RB. Proposed new method of analysis. In: Bennett AG, Rabbetts RB, eds. *Clinical Visual Optics*. London, England, Butterworth, 1984; 437
16. Holladay JT, Dudeja DR, Koch DD. Evaluating and reporting astigmatism for individual and aggregate data. *J Cataract Refract Surg* 1998; 24:57–65
17. Thibos LN, Horner D. Power vector analysis of the optical outcome of refractive surgery. *J Cataract Refract Surg* 2001; 27:80–85
18. Serdarevic ON, Renard GJ, Pouliquen Y. Randomized clinical trial comparing astigmatism and visual rehabilitation after penetrating keratoplasty with and without intraoperative suture adjustment. *Ophthalmology* 1994; 101:990–999
19. Lipener C, Kwitko S, Uras R, Zamboni F, Lewinski R, Araújo A, Pereira Lima R Jr. Adaptação de lentes de contato pós-transplante de córnea [Fitting contact lenses after penetrating keratoplasty]. *Arq Bras Oftalmol* 1990; 53:41–44
20. Huang PYC, Huang PT, Astle WF, Ingram AD, Hèbert A, Huang J, Ruddell S. Laser-assisted subepithelial keratectomy and photorefractive keratectomy for post-penetrating keratoplasty myopia and astigmatism in adults. *J Cataract Refract Surg* 2011; 37:335–340
21. Malecha MA, Holland EJ. Correction of myopia and astigmatism after penetrating keratoplasty with laser in situ keratomileusis. *Cornea* 2002; 21:564–569

22. Genvert GI, Cohen EJ, Arentsen JJ, Laibson PR. Fitting gas-permeable contact lenses after penetrating keratoplasty. *Am J Ophthalmol* 1985; 99:511–514
23. Lee HS, Kim MS. Factors related to the correction of astigmatism by LASIK after penetrating keratoplasty. *J Refract Surg* 2010; 26:960–965
24. Alfonso JF, Lisa C, Abdelhamid A, Montés-Micó R, Poo-López A, Ferrer-Blasco T. Posterior chamber phakic intraocular lenses after penetrating keratoplasty. *J Cataract Refract Surg* 2009; 35:1166–1173
25. Coskunseven E, Kymionis GD, Talu H, Aslan E, Diakonis VF, Bouzoukis DI, Pallikaris I. Intrastromal corneal ring implantation with the femtosecond laser in a post-keratoplasty patient with recurrent keratoconus. *J Cataract Refract Surg* 2007; 33:1808–1810
26. Prazeres TMB, Cezar da Luz Souza A, Pereira NC, Ursulino F, Grubenmacher L, Barbosa de Souza L. Intrastromal corneal ring segment implantation by femtosecond laser for the correction of residual astigmatism after penetrating keratoplasty. *Cornea* 2011; 30:1293–1297
27. Chang DH, Hardten DR. Refractive surgery after corneal transplantation. *Curr Opin Ophthalmol* 2005; 16:251–255
28. Barraquer JI. Modification of refraction by means of intracorneal inclusions. *Int Ophthalmol Clin* 1966; 6(1):53–78
29. Coskunseven E, Kymionis GD, Jankov MR II. Complications of intra corneal ring segment implantation with femtosecond laser channel creation in patients with keratoconus (explanations and solutions). *J Emmetropia* 2010; 1:221–228. Available at: <http://www.journalofemmetropia.org/2171-4703/jemmetropia.2010.1.221.228.pdf>. Accessed January 28, 2012