

Long-term follow-up of intrastromal corneal ring segments in keratoconus

Leonardo Torquetti, MD, PhD, Rodrigo Fabri Berbel, MD, Paulo Ferrara, MD, PhD

PURPOSE: To report the long-term follow-up of Ferrara intrastromal corneal ring segment (ICRS) implantation for the management of keratoconus.

SETTING: Private clinic, Belo Horizonte, Brazil.

METHODS: This study comprised patients with keratoconus who completed at least 5 years of follow-up. One or 2 ICRS were inserted in the cornea, embracing the keratoconus area. Statistical analysis included preoperative and postoperative uncorrected distance visual acuity (UDVA), corrected distance visual acuity (CDVA), and keratometry (K) values.

RESULTS: Thirty-five eyes of 28 patients were evaluated. The mean UDVA improved from 0.15 preoperatively to 0.31 postoperatively and the mean CDVA, from 0.41 to 0.62, respectively; the increases were statistically significant ($P = .003$ and $P = .002$, respectively). Corneal topography showed corneal flattening in all eyes. The mean minimum K value decreased from 48.99 D preoperatively to 44.45 D postoperatively and the mean maximum K value, from 54.07 D to 48.09 D, respectively; the decreases were statistically significant (both $P = .000$).

CONCLUSIONS: Five years after ICRS implantation, the UDVA and CDVA were improved in eyes with keratoconus. There was significant postoperative corneal flattening that remained stable over the follow-up period.

J Cataract Refract Surg 2009; 35:1768–1773 © 2009 ASCRS and ESCRS

Keratoconus is a corneal ectatic disease characterized by noninflammatory progressive thinning of unknown cause in which the cornea assumes a conical shape. Intrastromal corneal ring segments (ICRS) have been used to correct ectatic corneal diseases by reducing corneal steepening, decreasing irregular astigmatism, and improving visual acuity.^{1–7} In addition, ICRS implantation is a surgical alternative to delay, if not eliminate, the need for lamellar or penetrating keratoplasty.

Many studies report the efficacy of ICRS implantation in treating many corneal conditions, such as keratoconus,^{1–7} corneal ectasia after laser in situ keratomileusis,⁸ ectasia after radial keratotomy,⁹ astigmatism,¹⁰ and myopia.^{11–14} The changes in corneal structure induced by additive technologies can be roughly predicted by the Barraquer thickness law¹⁵; that is, when material is added to the periphery of the cornea or an equal amount of material is removed from the central area, a flattening effect is achieved. The corrective result varies in direct proportion to the thickness of the ICRS and in inverse proportion to its diameter. The thicker and smaller the diameter of the ring, the higher the corrective result.

This study was performed to evaluate the long-term visual acuity and mechanical stability results of Ferrara ICRS (Ferrara Ophthalmics) implantation in eyes with keratoconus. The minimum follow-up was 5 years.

PATIENTS AND METHODS

This retrospective study evaluated the records of patients with keratoconus who completed at least 5 years of follow-up. The main indication for ICRS implantation was contact

Submitted: December 8, 2008.

Final revision submitted: April 30, 2009.

Accepted: May 5, 2009.

From a private clinic, Belo Horizonte, Brazil.

Dr. Ferrara has a financial interest in the Ferrara intrastromal corneal ring. No other author has a financial or proprietary interest in any material or method mentioned.

Corresponding author: Paulo Ferrara, MD, PhD, Clinica de Olhos Paulo Ferrara, Avenida Contorno 4747, Sala 615, LifeCenter, Funcionários, Belo Horizonte, MG-30110-031, Brazil. E-mail: pferrara@ferrararing.com.br.

Table 1. Nomogram for selecting ICRS.

Cone	Diameter (mm)	Thickness (mm)	Intended Correction (D)
	5.00	0.150	−2.00 to −4.00
Cone I	5.00	0.200	−4.25 to −6.00
Cone II	5.00	0.250	−6.25 to −8.00
Cone III	5.00	0.300	−8.25 to −10.00
Cone IV	5.00	0.350	−10.25 to −12.00

lens intolerance, progression of ectasia, or both. Progression of keratoconus was defined as worsening of uncorrected distance visual acuity (UDVA) and corrected distance visual acuity (CDVA), progressive intolerance to contact lens wear, and progressive corneal steepening documented by topography. Patients were excluded if any of the following criteria applied after a preoperative examination: advanced keratoconus with curvatures greater than 62.00 diopters (D) and significant apical opacity and scarring, hydrops, thin corneas, thickness less than 300 μ m in the ICRS track, intense atopia (which should be treated before ICRS implantation), and ongoing local or systemic infection.

The Ferrara ICRS used in this study are made of poly(methyl methacrylate)–Perspex CQ acrylic segments. They vary in thickness (0.15 mm, 0.20 mm, 0.30 mm, and 0.35 mm). The segment cross-section is triangular, and the base for every thickness was 0.60 mm wide. The segments used in this study had 160 degrees of arc.

Outcome data included preoperative and postoperative UDVA, CDVA, and keratometry (K) values. Corneal topography was obtained using the EyeMap system (Alcon, Inc.) and Pentacam device (Oculus).

All surgery was performed by the same surgeon (P.F.) using a standard technique that has been described.^{1–5} The ICRS were implanted according to a previously described nomogram.¹⁶ Basically, the ring selection was dependent on the ametropia and the degree of keratoconus evolution (Table 1). The 350 μ m ring is no longer used but was used in some cases in this study. The current nomogram is based on the position of the conus on the cornea (Figure 1), topographic astigmatism, and the pachymetric map.

Postoperative medication comprised ketorolac drops every 15 minutes for 3 hours, dexamethasone 0.1%–moxifloxacin 0.3% or ciprofloxacin drops every 4 hours for 7 days, and hypromellose drops every 6 hours for 30 days.

Statistical analysis was performed using Minitab software (Minitab, Inc.). The Student *t* test for paired data was used to compare preoperative and postoperative results. Only data collected up to the fifth year were considered in this analysis.

RESULTS

Thirty-five eyes of 28 patients with keratoconus were evaluated. Seven patients had bilateral surgery and 21 patients, unilateral surgery. The surgeries in bilateral cases were performed from 1 day to 3 years apart. In unilateral cases, the eye in which an ICRS was not implanted was corrected with spectacles or contact lenses. The follow-up ranged from 5 to 12 years.





Map	Distribution of Ectasia	Description
	0%/100%	All the ectatic area is located at one side of the cornea.
	25%/75%	75% of the ectatic area is located at one side of the cornea.
	33%/66%	66% of the ectatic area is located at one side of the cornea.
	50%/50%	The ectatic area is symmetrically distributed on the cornea.

Figure 1. Current nomogram. Selection of the ICRS is according to the distribution of the corneal ectasia.

A 0.15 mm segment was implanted in 11 eyes, a 0.20 mm segment in 5 eyes, a 0.25 mm segment in 10 eyes, a 0.30 mm segment in 6 eyes, and a 0.35 mm segment in 3 eyes. No perioperative or postoperative complications occurred.

Table 2 shows the mean UDVA and CDVA over time. The mean UDVA improved up to the 4-year follow-up, at which time it decreased and then remained stable to the 5-year follow-up. The mean increase in UDVA from preoperatively to 5 years postoperatively was statistically significant ($P = .003$). The UDVA was unchanged in 9 eyes; 22 eyes gained 1 or more lines of UDVA, and 4 eyes lost 1 or 2 lines.

The mean CDVA improved up to the 3-year follow-up, at which time it remained stable until the 5-year follow-up, when it decreased slightly. The mean increase in CDVA from preoperatively to 5 years postoperatively was statistically significant ($P = .002$) (Figure 2). The CDVA was unchanged in 5 eyes; 26 eyes gained 1 or more lines of CDVA, and 4 eyes lost 1 or 2 lines.

Corneal topography showed corneal flattening in all eyes (Figures 3 to 5). The decreases in the mean minimum K and mean maximum K values were statistically significant (both $P = .000$) (Table 2).

DISCUSSION

Preliminary studies found ICRS implantation to be an effective treatment for astigmatism and myopia with astigmatism,¹⁵ preserving CDVA and giving stable results over time.¹⁶ The objective of the additive technology is to reinforce the cornea, decrease corneal irregularity, and improve visual acuity.

The results in our study agree with those in other studies. Miranda et al.¹⁷ reported a significant reduction in mean central corneal curvature postoperatively; CDVA improved in 87.1% of eyes and UDVA in

Table 2. Preoperative and postoperative data.

Parameter	Mean \pm SD						
	Preoperative	Postoperative					
		1 Month	1 Year	2 Years	3 Years	4 Years	5 Years
Maximum K (D)	54.07 \pm 7.34	49.36 \pm 6.66	48.22 \pm 4.73	47.84 \pm 4.98	47.06 \pm 4.90	47.83 \pm 6.56	48.09 \pm 5.92
Minimum K (D)	48.49 \pm 5.06	45.27 \pm 5.39	43.89 \pm 4.59	44.01 \pm 3.83	43.12 \pm 4.82	44.14 \pm 5.75	44.45 \pm 5.97
Mean K (D)	51.27 \pm 5.91	47.29 \pm 5.91	45.88 \pm 4.52	45.71 \pm 4.20	44.78 \pm 4.55	45.97 \pm 6.21	46.24 \pm 5.89
UDVA	0.15 \pm 0.15	0.25 \pm 0.19	0.29 \pm 0.17	0.29 \pm 0.19	0.33 \pm 0.17	0.30 \pm 0.22	0.31 \pm 0.23
CDVA	0.41 \pm 0.25	0.56 \pm 0.24	0.61 \pm 0.24	0.63 \pm 0.22	0.62 \pm 0.20	0.62 \pm 0.16	0.59 \pm 0.19

CDVA = corrected distance visual acuity; K = keratometry reading; NA = not available; UDVA = uncorrected distance visual acuity

80.6%. Siganos et al.⁴ found an increase in the mean UDVA, from 0.07 ± 0.08 preoperatively to 0.20 ± 0.13 at 1 year and 0.30 ± 0.21 at 6 months; the mean CDVA improved from 0.37 ± 0.25 preoperatively to 0.50 ± 0.43 and 0.60 ± 0.17 , respectively. Kwitko and Severo¹⁸ report that after Ferrara ICRS implantation in eyes with keratoconus, CDVA improved in 86.4% of eyes, was unchanged in 1.9%, and was worse in 11.7%; UDVA improved in 86.4% of eyes, was unchanged in 7.8%, and was worse in 5.8%. The mean corneal curvature decreased from 48.76 ± 3.97 D preoperatively to 43.17 ± 4.79 D postoperatively.

The nomogram for implanting Ferrara ICRS has evolved as knowledge about the predictability of results has grown. Initially, surgeons implanted a pair of symmetrical segments in every case. The incision was always placed in the steep meridian to take advantage of the coupling effect achieved by the segments. In the first nomogram, the ICRS was selected based on the grade of keratoconus only; thus, the most suitable ICRS for eyes with grade 1 keratoconus was 150 μ m and for eyes with grade 4 keratoconus, 350 μ m. Some cases of extrusion occurred in eyes with grade 4

keratoconus because the cornea is usually very thin in these eyes and the thick segment was not properly fitted in the corneal stroma in some cases.

In the second-generation nomogram, ring selection took refraction into account in addition to the distribution of the ectatic area of the cornea. Therefore, as the spherical equivalent increased, the thickness of the selected ring increased. However, in many keratoconus eyes, myopia and astigmatism were caused not by ectasia but by an increase in the axial length of the eye (axial myopia). In these cases, hypercorrection resulted because a thick ICRS was implanted when a thinner one should be indicated.

In the third and current generation of the nomogram, ring selection is based on corneal thickness, the amount of topographic corneal astigmatism (simulated K), and the distribution of the ectatic area on the cornea (Table 3). Implantation of an ICRS can be considered as an orthopedic procedure, and refraction is not important in this nomogram. For symmetric bow-tie patterns of keratoconus, 2 equal segments are selected. For peripheral cones, the most common type, asymmetrical segments are selected. Segment

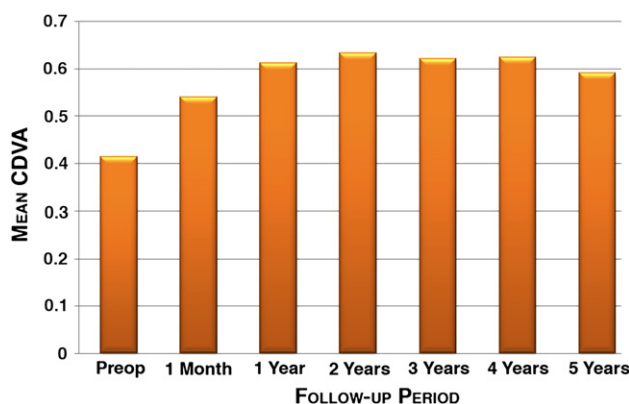


Figure 2. Mean CDVA over time (CDVA = corrected distance visual acuity).

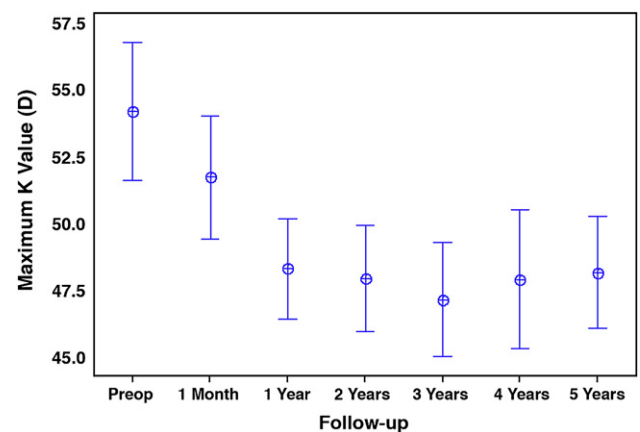


Figure 3. Mean maximum K value over time (K = keratometry).

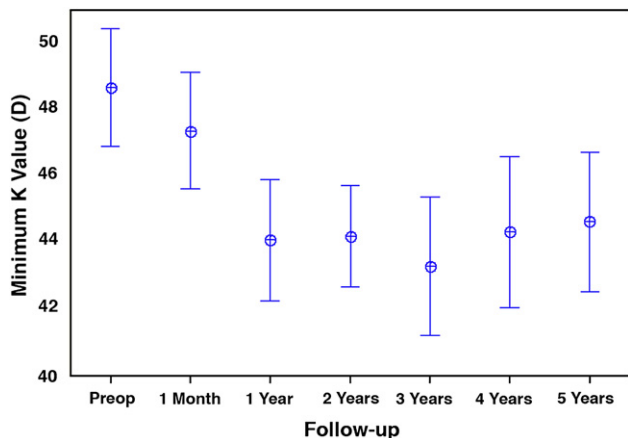


Figure 4. Mean minimum K value over time (K = keratometry).

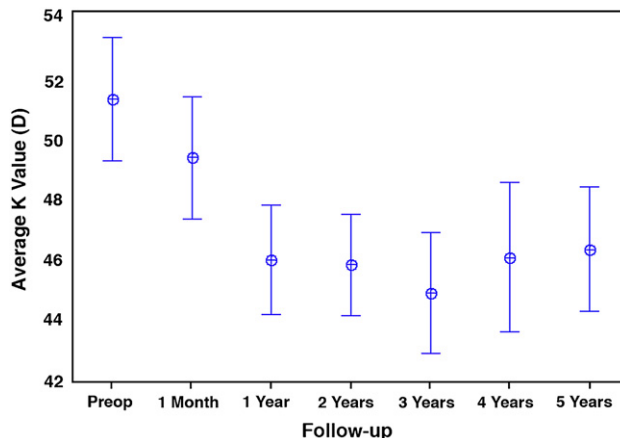


Figure 5. Mean average K value over time (K = keratometry).

thickness must not exceed 50% of the thickness of the cornea on the track of the ring.

The current nomogram is the result of almost 10 years of study of more than 6000 patients. The results with this nomogram are very satisfactory and reproducible; thinner segments can be used to achieve a significant amount of corneal regularization.

We did not evaluate the complication rate in this study. However, postoperative complications can occur after ICRS implantation. The complications can be related to the surgical technique, the nomogram, and the ICRS itself. Complications related to the surgical technique are extrusion (due to a shallow tunnel), infection, bad ICRS centration (incorrect placement), ICRS migration and misplacement, and asymmetry of the segments. Complications related to the nomogram are linked to the corneal biomechanics and include overcorrection and undercorrection. Although the predictability of postoperative results is high, overcorrection and undercorrection can occur as a result of the differing viscoelastic and biomechanical profiles of keratoconic corneas. The complications related to ICRS itself are halos, glare, periannular deposits, and neovascularization. Halos are reported by 10% of patients and can be related to the pupil size. This symptom tends to fade or diminish over time. In very symptomatic cases, we usually prescribe pilocarpine or brimonidine tartrate at night to constrict the pupil and alleviate the undesired reflexes. We recently developed segments with a yellow filter in the matrix to avoid blue light at night, which can significantly decrease the incidence of glare and halos.

Periannular opacities are small white debris that lies along the internal face of the segment. They usually are seen in cases of significant surgical trauma (ie, large tunnels or excessive ICRS thickness). They do not tend to grow and do not decrease visual performance.

Neovascularization of the stromal tunnel is rare and usually occurs in atopic patients. We have used subconjunctival bevacizumab to treat this complication with reasonable results.¹⁹⁻²²

Kwitko and Severo¹⁸ reported decentration of Ferrara ICRS in 3.9% of cases, segment extrusion in 19.6%, and bacterial keratitis in 1.9%. The authors suggest that most of the complications related to surgical technique were caused by the surgeon's learning curve and the differing healing processes of keratoconic corneas. Once the surgical procedure is mastered, the complication rate related to the surgery is very low. The surgical steps must be followed carefully to avoid surgery-related complications. For example, the

Table 3. Segment thickness choices.

Condition/Topographic Astigmatism (D)	Segment Thickness (µm)
Symmetric bow-tie keratoconus	
<2.00	150/150
2.25 to 4.00	200/200
4.25 to 6.00	250/250
>6.25	300/300
Cones with 0/100% and 25/75% of asymmetry index	
<2.00	None/150
2.25 to 4.00	None/200
4.25 to 6.00	None/250
6.25 to 8.00	None/300
8.25 to 10.00	150/250
>10.00	200/300
Cones with 0/100% and 33/66% of asymmetry index	
<2.00	None/150
2.25 to 4.00	150/200
4.25 to 6.00	200/250
6.25 to 8.00	250/300

Table 4. Comparison of Ferrara and Intacs ICRS studies with long-term results.

Parameter	Mean \pm SD								
	Preoperative			Postoperative					
	Present Study (Ferrara)	Alio et al. ²³ (Intacs)	Colin and Mallet ²⁵ (Intacs)	1 Year			2 Years		
				Present Study (Ferrara)	Alio et al. ²³ (Intacs)	Colin and Mallet ²⁵ (Intacs)	Present Study (Ferrara)	Alio et al. ²³ (Intacs)	Colin and Mallet ²⁵ (Intacs)
Maximum K (D)	54.07 \pm 7.34	51.07 \pm 3.62	53.6 \pm 5.8	48.22 \pm 4.73	47.84 \pm 3.73	48.5 \pm 5.6	47.84 \pm 4.98	47.69 \pm 3.80	48.7 \pm 5.2
Minimum K (D)	48.49 \pm 5.06	45.84 \pm 3.48	46.7 \pm 6.6	43.89 \pm 4.59	43.76 \pm 3.59	44.3 \pm 5.4	44.01 \pm 3.83	44.10 \pm 2.55	44.9 \pm 4.9
Mean K (D)	51.27 \pm 5.91	48.46 \pm 3.27	50.1 \pm 5.6	45.88 \pm 4.52	45.80 \pm 3.52	46.4 \pm 5.3	45.71 \pm 4.20	45.90 \pm 2.38	46.8 \pm 4.9
UDVA	0.15 \pm 0.15	NA	0.10*	0.29 \pm 0.17	NA	0.20*	0.29 \pm 0.19	NA	0.20*
CDVA	0.41 \pm 0.25	0.46 \pm 0.20	0.35*	0.61 \pm 0.24	0.66	>0.50*	0.63 \pm 0.22	0.66	>0.50*

CDVA = corrected distance visual acuity; K = keratometry reading; NA = not available UDVA = uncorrected distance visual acuity

*Approximate data; mean not given in the original study, only the range reported

stromal tunnel must be constructed with the adjustable diamond knife set at 80% of local corneal thickness to reduce the risk for a shallow tunnel and subsequent ICRS extrusion.

In general, the thickest segment of a pair of ICRS should not exceed half thickness of the cornea in its bed. In such case, a pair of ICRS that fits this condition must be chosen, even if the achieved correction is smaller than desired.

Based on personal unpublished data, approximately 5% of patients require subsequent penetrating or lamellar keratoplasty due to progressive corneal scarring, despite proper ICRS implantation. These patients usually had ICRS implantation at a very advanced phase of the disease and required the subsequent surgery not necessarily because the keratoconus evolved but rather because of an unsatisfactory visual outcome.

We believe that this is the first study to show the long-term results (>5 years) of Ferrara ICRS implantation in patients with keratoconus. The few previous long-term studies of ICRS^{23–25} were of Intacs (Addition Technology, Inc.) implantation.

Alió et al.²³ performed a retrospective study to evaluate the long-term (up to 48 months) results after Intacs implantation in patients with keratoconus. The mean CDVA increased significantly ($P < .01$), from 0.46 (20/50) preoperatively to 0.66 (20/30) 6 months postoperatively. The 3.13 D decrease in the mean average K value was statistically significant ($P < .01$). Comparison of 6-month and 36-month results shows refractive and topographic stability.

Kymionis et al.²⁴ studied 17 eyes with keratoconus that had Intacs implantation. The preoperative UDVA was 20/50 or worse in all eyes; at the last

follow-up examination, the UDVA was 20/50 or better in 59% of eyes. More than half the eyes (59%) gained lines (1 to 8) of visual acuity.

The long-term stability in our study is comparable to that found in other studies of ICRS implantation (Table 4).^{23–25} As shown in previous studies, the ICRS flattens the cornea, and the effect persists for a long period. There is no significant re-steepening of the cornea over time.

In conclusion, implantation of Ferrara ICRS resulted in topographic and visual stability, delayed the progression of keratoconus, and eliminated or at least postponed the need for corneal grafting surgery. Further studies with larger samples and a longer follow-up are needed to confirm these results.

REFERENCES

- Colin J, Velou S. Implantation of Intacs and a refractive intraocular lens to correct keratoconus. *J Cataract Refract Surg* 2003; 29:832–834
- Asbell PA, Uçakhan ÖÖ. Long-term follow-up of Intacs from a single center. *J Cataract Refract Surg* 2001; 27:1456–1468
- Colin J, Cochener B, Savary G, Malet F. Correcting keratoconus with intracorneal rings. *J Cataract Refract Surg* 2000; 26: 1117–1122
- Siganos D, Ferrara P, Chatzinikolas K, Bessis N, Papastergiou G. Ferrara intrastromal corneal rings for the correction of keratoconus. *J Cataract Refract Surg* 2002; 28:1947–1951
- Colin J, Cochener B, Savary G, Malet F, Holmes-Higgin D. INTACS inserts for treating keratoconus; one-year results. *Ophthalmology* 2001; 108:1409–1414
- Siganos CS, Kymionis GD, Kartakis N, Theodorakis MA, Astyrakakis N, Pallikaris IG. Management of keratoconus with Intacs. *Am J Ophthalmol* 2003; 135:64–70
- Assil KK, Barrett AM, Fouraker BD, Schanzlin DJ. One-year results of the intrastromal corneal ring in nonfunctional human eyes; the Intrastromal Corneal Ring Study Group. *Arch Ophthalmol* 1995; 113:159–167

8. Siganos CS, Kymionis GD, Astyrakakis N, Pallikaris IG. Management of corneal ectasia after laser in situ keratomileusis with INTACS. *J Refract Surg* 2002; 18:43–46
9. Dias de Silva FB, França Alves EA, Ferrara de Almeida Cunha P. Utilização do Anel de Ferrara na estabilização e correção da ectasia corneana pós PRK. (Use of Ferrara's ring in the stabilization and correction of corneal ectasia after PRK). *Arq Bras Oftalmol* 2000; 63:215–218. Available at: <http://www.scielo.br/pdf/abo/v63n3/13587.pdf>.
10. Ruckhofer J, Stoiber J, Twa MD, Grabner G. Correction of astigmatism with short arc-length intrastromal corneal ring segments; preliminary results. *Ophthalmology* 2003; 110:516–524
11. Nosé W, Neves RA, Burris TE, Schanzlin DJ, Belfort R Jr. Intrastromal corneal ring: 12-month sighted myopic eyes. *J Refract Surg* 1996; 12:20–28
12. Schanzlin DJ, Asbell PA, Burris TE, Durrie DS. The intrastromal ring segments; phase II results for the correction of myopia. *Ophthalmology* 1997; 104:1067–1078
13. Holmes-Higgin DK, Burris TE, Lapidus JA, Greenlick MR. Risk factors for self-reported visual symptoms with Intacs inserts for myopia. *Ophthalmology* 2002; 109:46–56
14. Asbell PA, Uçakhan ÖÖ, Abbott RL, Assil KA, Burris TE, Durrie DS, Lindstrom RL, Schanzlin DJ, Verity SM, Waring GO III. Intrastromal corneal ring segments: reversibility of refractive effect. *J Refract Surg* 2001; 17:25–31
15. Barraquer JI. Modification of refraction by means of intracorneal inclusions. *Int Ophthalmol Clin* 1966; 6(1):53–78
16. Ferrara de A Cunha P. Técnica cirúrgica para correção de miopia; Anel corneano intra-estromal. (Myopia correction with intrastromal corneal ring). *Rev Bras Oftalmol* 1995; 54:577–588
17. Miranda D, Sartori M, Francesconi C, Allemann N, Ferrara P, Campos M. Ferrara intrastromal corneal ring segments for severe keratoconus. *J Refract Surg* 2003; 19:645–653
18. Kwitko S, Severo NS. Ferrara intracorneal ring segments for keratoconus. *J Cataract Refract Surg* 2004; 30:812–820
19. Dastjerdi MH, Al-Arfaj KM, Nallasamy N, Hamrah P, Jurkunas UV, Pineda R II, Pavan-Langston D, Dana R. Topical bevacizumab in the treatment of corneal neovascularization; results of a prospective, open-label, noncomparative study. *Arch Ophthalmol* 2009; 127:381–389
20. Mackenzie SE, Tucker WR, Poole TRG. Bevacizumab (Avastin) for corneal neovascularization—corneal light shield soaked application. *Cornea* 2009; 28:246–247
21. Chen W-L, Lin C-T, Lin N-T, Tu I-H, Li J-W, Chow L-P, Liu K-R, Hu F-R. Subconjunctival injection of bevacizumab (Avastin) on corneal neovascularization in different rabbit models of corneal angiogenesis. *Invest Ophthalmol Vis Sci* 2009; 50:1659–1665
22. Doctor PP, Bhat PV, Foster CS. Subconjunctival bevacizumab for corneal neovascularization. *Cornea* 2008; 27:992–995
23. Alió JI, Shabayek MH, Artola A. Intracorneal ring segments for keratoconus correction: long-term follow-up. *J Cataract Refract Surg* 2006; 32:978–985
24. Kymionis GD, Siganos CS, Tsiklis NS, Anastasakis A, Yoo SH, Pallikaris AI, Astyrakakis N, Pallikaris IG. Long-term follow-up of Intacs in keratoconus. *Am J Ophthalmol* 2007; 143:236–244
25. Colin J, Malet F. Intacs for the correction of keratoconus: two-year follow-up. *J Cataract Refract Surg* 2007; 33:69–74



First author:
Leonardo Torquetti, MD, PhD
*Private clinic, Belo Horizonte,
 Brazil*