

New technique of Deep Anterior Lamellar Keratoplasty

Paulo Ferrara, MD, PhD¹; Leonardo Torquetti, MD, PhD²; Leandro Cunha, MD²

We present a simple, effective and reproducible technique of deep anterior lamellar keratoplasty. Using a diamond knife, set at 90% of corneal thickness at (90 degrees meridian), at 8 mm optic zone, a radial incision was done and corneal pockets were created. A 6.0 nylon preloaded spatula was then inserted into the corneal pocket and in a counterclockwise direction rotated in 360° to create a deep stromal tunnel. A partial-thickness 8 mm trephination was done. The spatula was removed from the tunnel and the nylon wire was pulled from both sides of the radial incision to dissect deep to the corneal stroma leaving little residual stroma over the Descemet's membrane. The residual anterior stroma is removed with a Vannas scissors. The donor button is sutured. The main advantages of this technique are the very low learning curve and the regular stromal dissection with almost no residual tissue over the Descemet's membrane.

KEYWORDS: Deep anterior lamellar keratoplasty, keratoconus.

J Emmetropia 2011; 2: 79-83

INTRODUCTION

Deep anterior lamellar keratoplasty (DALK) is a surgical technique for cornea replacement, which the healthy host corneal endothelium is preserved. Keratoconus patients are those who benefit most from a successful DALK procedure, once the endothelium of these patients is usually normal and should therefore be maintained.

Several studies comparing visual outcomes between penetrating keratoplasty (PK) and DALK have shown similar results¹⁻⁴. Initially, DALK was performed using manual corneal dissection⁵. The greatest limitation of early DALK techniques was that they left variable amounts of residual stroma. This provided a scaffold for vascular ingrowth or led to variable amounts of postoperative scarring in the interface due to the remaining vessels. Also, the uneven or irregular dissection plane could impair visual acuity. The main disadvantage of DALK is the significant learning curve to master the technique. Moreover, it is time-consuming

procedure, especially when the stroma has to be manually separated from the Descemet's membrane.

Anwar and Teichmann's⁶ big-bubble technique of injecting air into the corneal stroma to isolate Descemet's membrane markedly improved DALK outcomes. Removing the overlying stroma completely created a clear graft interface without irregularities. Visual outcomes are excellent, and postoperative interface problems from vascularization of the recipient corneal bed are minimal.

A variant of the big-bubble technique in deep anterior lamellar keratoplasty (DALK) assisted by the femtosecond laser has been described, with good and reproducible results^{7,8}.

The present technique allows a deep and smooth separation of corneal stroma from Descemet's membrane, by an interlamella cleavage plane created by a nylon wire.

SURGICAL TECHNIQUE

The surgical procedure is done under peribulbar anesthesia. The surgery shares some steps of intrastromal corneal ring segments implantation. Initially, using a diamond knife, set at 90% of corneal thickness (90 degrees meridian), at 8 mm optic zone (fig. 1A), a 0.9 mm radial incision was formed and corneal pockets were created using the Ferrara spreader (fig. 1B and 1C). A 6.0 nylon preloaded spatula was then inserted into the corneal pocket and in a counterclockwise direction rotated in 360° to create a deep stromal tunnel, in a similar manner as in the manual technique for intrastromal corneal ring segments implantation^{9,10} (fig. 1D, 1E and 1F). After the tunnelization the spat-

Submitted: 2/13/2011

Revised: 4/6/2011

Accepted: 4/25/2011

¹ Paulo Ferrara Eye Clinic. Director.

² Paulo Ferrara Eye Clinic. Assistant.

No financial support was provided for this study.

Correspondence to: Paulo Ferrara, MD, PhD. Paulo Ferrara Eye Clinic, Contorno Ave 4747, Suite 615, Lifecenter – Funcionários – Belo Horizonte – MG - 30110-031 – Brasil – pferrara@ferrararing.com.br

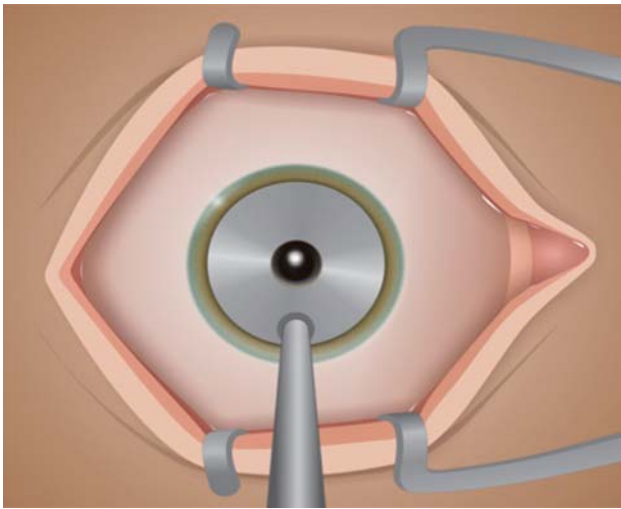


Figure 1A.

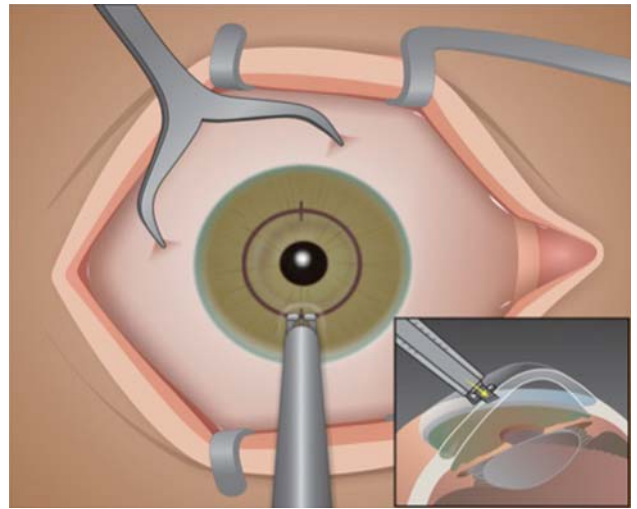


Figure 1B.

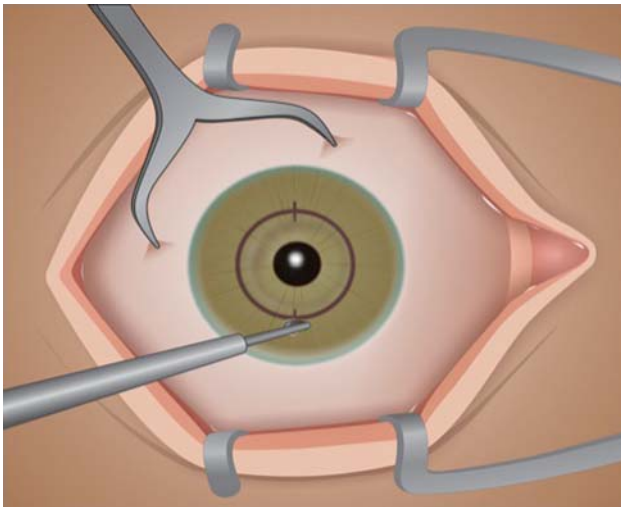


Figure 1C.

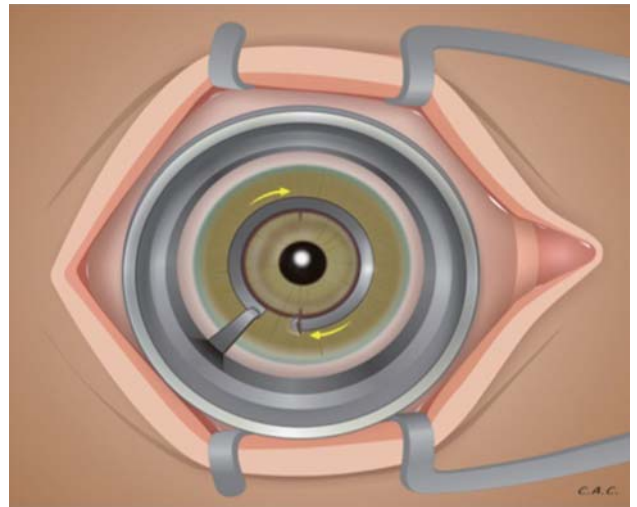


Figure 1D.

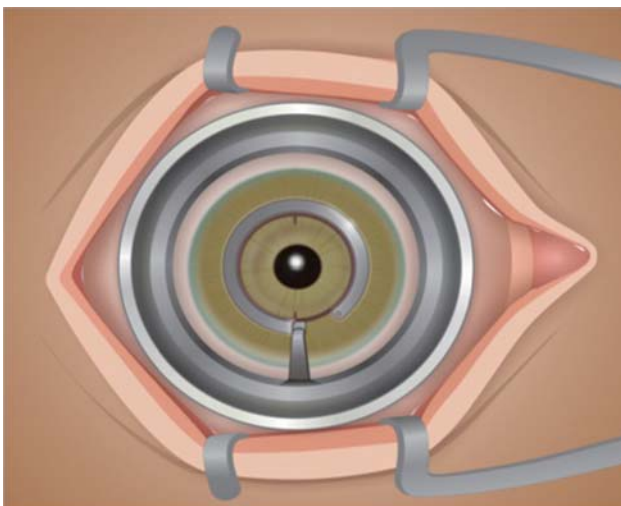


Figure 1E.

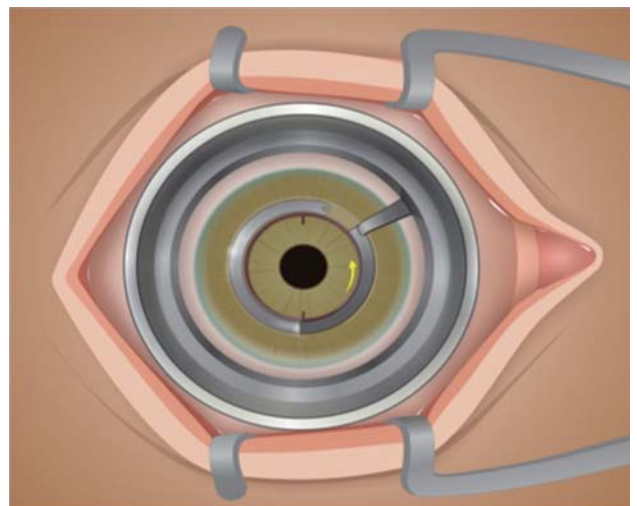


Figure 1F.

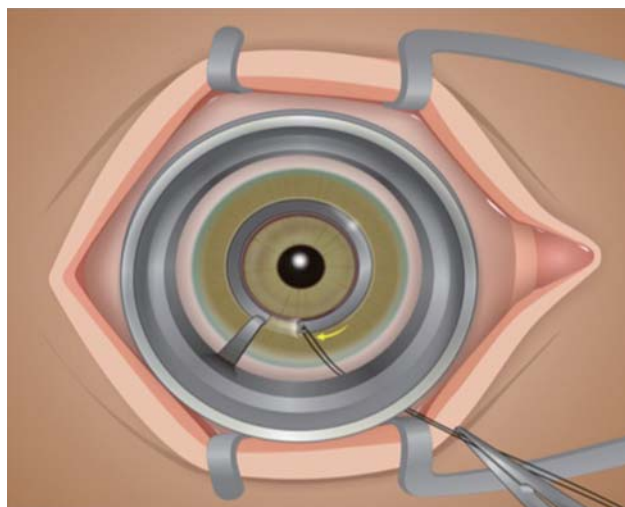


Figure 1G.

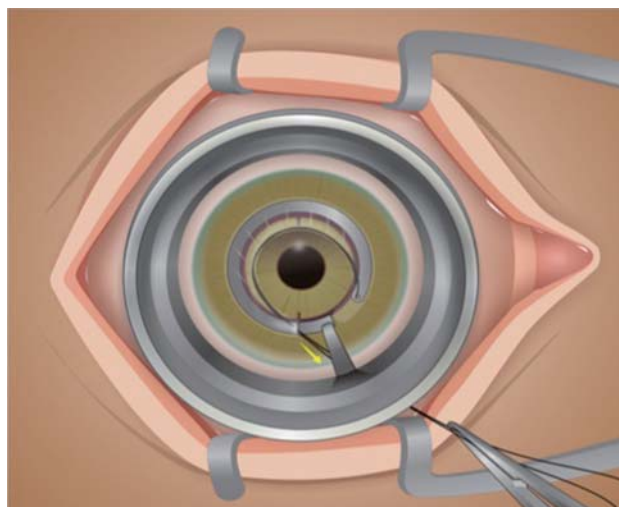


Figure 1H.

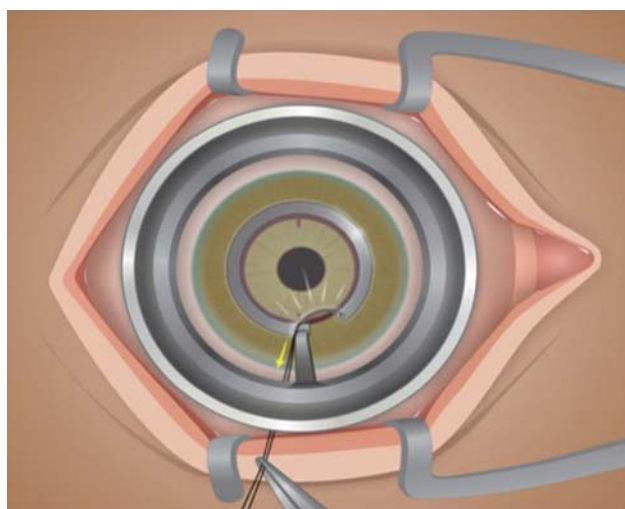


Figure 1I.

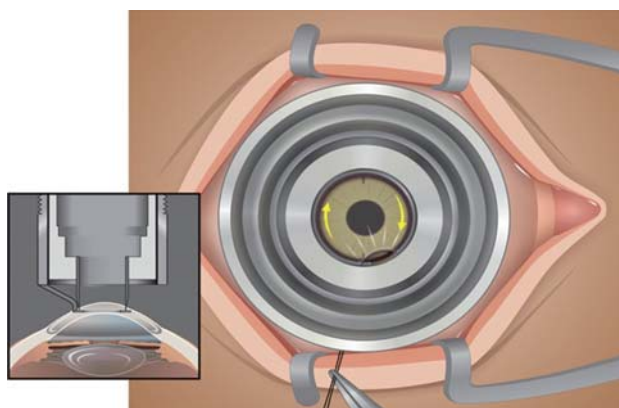


Figure 1J.

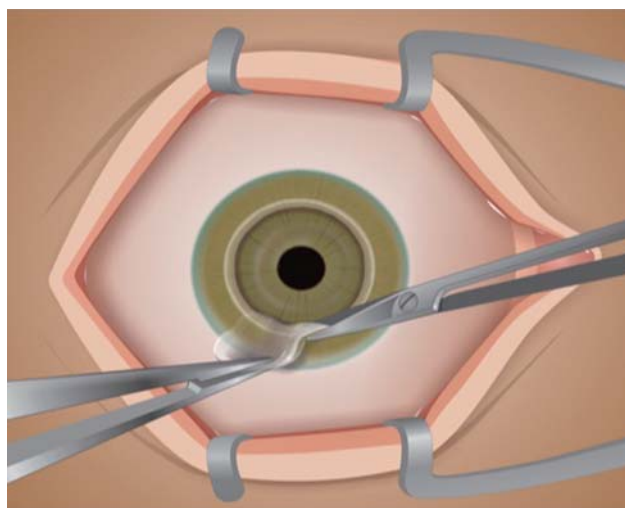


Figure 1L.

ula was removed from the tunnel and the nylon wire was pulled from both sides of the radial incision to dissect deep to corneal stroma leaving only the Descemet's membrane (fig. 1G, 1H and 1I). A partial-thickness 8.0 mm trephination was done. The trephine was used to cut until it touches the spatula beneath the corneal stromal tunnel (fig. 1J). Blunt-tipped Vannas scissors were used to remove anterior stromal tissue along the edge of partial thickness trephination (fig. 1L).

The donor cornea was punched out from the endothelial side, oversized by 0.5 mm, comparing to recipient trephination. The donor button was sutured into place using a continuous or 16 interrupted 10-0 nylon sutures (fig. 1M and 1N), without removal of donor endothelium and Descemet's membrane.

Postoperative medication included Moxifloxacin and Prednisolone four times a day for a week and tapered for a period of 6 weeks. Lubricants were used several times a day. The sutures were removed 3 months after the surgery (fig. 2).

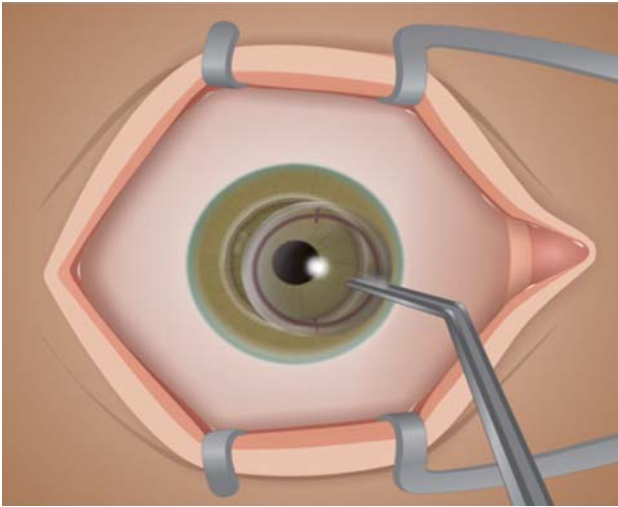


Figure 1M.

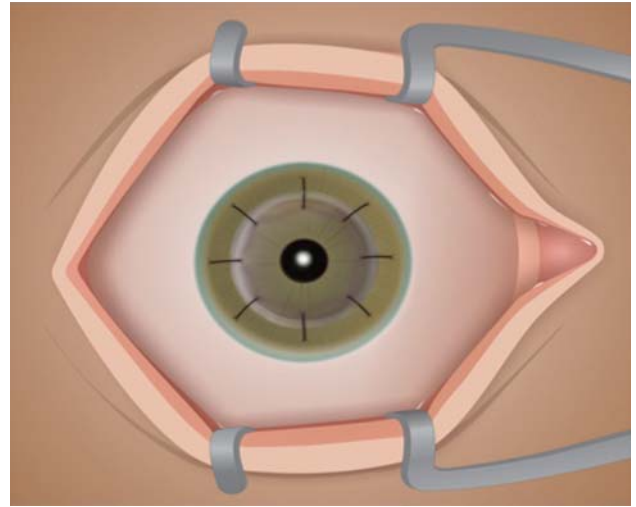


Figure 1N.

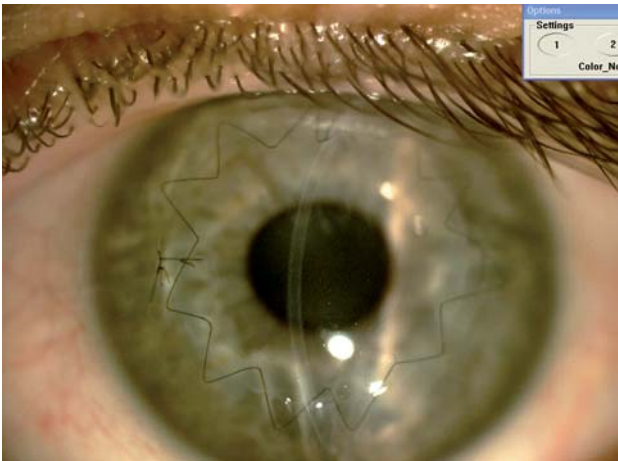


Figure 2.

DISCUSSION

Several techniques of lamellar keratoplasty have been described for keratoconus treatment. Anwar and Teichmann described the big-bubble technique to achieve separation of the Descemet's membrane from stroma after intrastromal air injection⁶. This technique has been widely used as a technique which provides rapid and satisfactory outcome that is comparable to PK². The technique allows a safe and direct access to Descemet's plane, with the advantages of shortening the surgical time, reducing the risk for perforation, and exposing a smooth, even surface of excellent optical quality. However, a big bubble is not formed in all cases^{6,11} and sometimes more than one injection of air into the deep stroma is required before cleavage between Descemet's membrane and the stroma is achieved. In these cases, repeated injections of air infiltrating the corneal stroma may cause complete whitening of the central cornea within the area of trephina-

tion, making it difficult to recognize the line of separation between Descemet's membrane and the stroma.

The increased safety of DALK and the potential for better visual outcomes in expertly performed procedures justifies the effort required for corneal surgeons to master the procedure and the additional operating room time. Another potential advantage is the utility of using tissue that is less optimal for PKP with lower endothelial cell counts or longer duration of death to preservation and time in preservation to expand the donor pool for optical keratoplasty.

The presented new technique of DALK eliminates any potential difficulties in recognizing formation of the big bubble during the surgery, which used to be the main challenge in the most widely used technique nowadays (big-bubble). Moreover, this new technique has a shorter learning curve for the surgeon, which is important as it can be a reliable technique when compared to other DALK techniques or even the PK.

REFERENCES

1. Krumeich JH, Knülle A, Krumeich BM. Deep anterior lamellar (DALK) vs. penetrating keratoplasty (PKP): a clinical and statistical analysis. *Klin Monbl Augenheilkd*. 2008 Jul; 225: 637-648.
2. Javadi MA, Feizi S, Yazdani S, Mirbabae F. Deep Anterior Lamellar Keratoplasty Versus Penetrating Keratoplasty for Keratoconus: A Clinical Trial. *Cornea*. 2010 Feb 17.
3. Jones MN, Armitage WJ, Ayliffe W, Larkin DF, Kaye SB; NHSBT Ocular Tissue Advisory Group and Contributing Ophthalmologists (OTAG Audit Study 5). Penetrating and deep anterior lamellar keratoplasty for keratoconus: a comparison of graft outcomes in the United kingdom. *Invest Ophthalmol Vis Sci*. 2009 Dec; 50: 5625-5629.
4. Han DC, Mehta JS, Por YM, Htoon HM, Tan DT. Comparison of outcomes of lamellar keratoplasty and penetrating keratoplasty in keratoconus. *Am J Ophthalmol*. 2009 Nov; 148: 744-751.e1.

5. Malbran E. Lamellar keratoplasty in keratoconus. *Int Ophthalmol Clin* 1966; 6: 99-109.
6. Anwar M, Teichmann KD. Big-bubble technique to bare Descemet's membrane in anterior lamellar keratoplasty. *J Cataract Refract Surg* 2002; 28: 398-403.
7. Chamberlain W, Cabezas M. Femtosecond-assisted deep anterior lamellar keratoplasty using big-bubble technique in a cornea with 16 radial keratotomy incisions. *Cornea*. 2011 Feb; 30: 233-6.
8. Buzzonetti L, Laborante A, Petrocelli G. Standardized big-bubble technique in deep anterior lamellar keratoplasty assisted by the femtosecond laser. *J Cataract Refract Surg*. 2010 Oct; 36(10): 1631-6.
9. Colin J, Cochener B, Savary G, et al. Correcting keratoconus with intracorneal rings. *J Cataract Refract Surg*. 2000; 26: 1117-1122.
10. Siganos D, Ferrara P, Chatzinikolas K, et al. Ferrara intrastromal corneal rings for the correction of keratoconus. *J Cataract Refract Surg* 2002; 28: 1947-1951.
11. Fogla R, Padmanabhan P. Results of deep lamellar keratoplasty using the big bubble technique in patients with keratoconus. *Am J Ophthalmol* 2006; 141: 254-259.



First author:
Paulo Ferrara, MD, PhD
*Paulo Ferrara Eye Clinic,
Brasil*